Thyroid Cancer Detection using Image Processing

Jagadeesh Saraf[1], Dr. Kalpana V[2]

[1]*PG Student, Dept of Electronics and Instrumentation, PDAEC Kalaburgi, Karnataka, INDIA*
[2]*Professor, Dept of Electronics and Instrumentation PDAEC Kalaburgi, Karnataka, INDIA*

Abstract:- **The objective of this paper is to classify the benign and malignant thyroid nodules in ultrasound images. Ultrasound imaging is one of the frequently used diagnosis tool to detect and classify abnormalities of the thyroid gland. In this proposed method we have following stages: Pre-processing, segmentation, feature extraction and classification. In pre processing we are resizing the input image by using nearest neighbor interpolation algorithm. With help of edge detection we are segmenting an input image. The textual features and shape based features are extracted in segmented part of an input image. Classification is done based on texture and shape features by using artificial neural network (ANN).**

Keywords: **- Thyroid ultrasound images, segmentation, textual and shape based feature extraction, artificial neural network (ANN).**

I. INTRODUCTION

Thyroid nodule is one of the most common endocrine carcinoma [1]. Ultrasonography has become the most widely used modality for detecting and diagnosing thyroid cancer, for its better reveal ability and distinction between benign and malignant nodules in pathological features compared to CT and MRI. With the rapid development of medical imaging technology, computer aided diagnosis (CAD) assists us solve the subjective diagnosing problem existing in current method, which highly depends on personal experience. As a well-trained 'expert', it has a wide application prospect in any situation when need to close the experience gap. The assessment of a thyroid nodule serves several purposes. The patient may experience symptoms from a functional or sizable lesion, or may be at risk of cancer. A thorough history and blood test for TSH, eventually combined with a technetium (Tc) scan, will promptly identify a hyperfunctioning nodule. Symptoms related to the size of a nodule are usually indicated by the patient, and may be crucial in the treatment-making process. Determining the risk of cancer in a nodule can be a more difficult concept, and the approach involves medical, rational, economic, and cultural considerations. It should be remembered that in dealing with a thyroid nodule, the evidence with regard to outcome, including the prevention of death, and morbidity, from thyroid cancer, is sparse. The natural course of a microcancer or small cancer is not known. They are both frequent findings in postmortem examinations that seem to have caused no morbidity to those who died from natural or other causes. Therefore neither common sense nor evidence supports the assumption that the health of a population or of an individual benefits from an overly aggressive approach to early or small cancers. For example; in the commonest cancer, papillary thyroid cancer (PTC), there is no evidence that treatment in the earliest stage offers a significant benefit compared with treatment at a slightly later point, when the increase in size of a suspicious nodule has provided evidence that the lesion is dynamically growing. In other words, while the patient may have a risk of cancer, indeed even in the presence of cancer, it is important to avoid causing undue fear to patients, and harm from invasive or unnecessary investigations. The appropriate timing of the assessment for a suspect follicular thyroid cancer (FTC) is equally unclear but is complicated by the fact that undue delay may lead to a scenario where distant metastases have become established from early haematogenous spread. For the less common medullary thyroid cancer (MTC) there is overwhelming evidence that early detection and treatment results in an improved outcome. For anaplastic thyroid cancer (ATC) only early treatment provides a chance of survival

II. METHODOLOGY

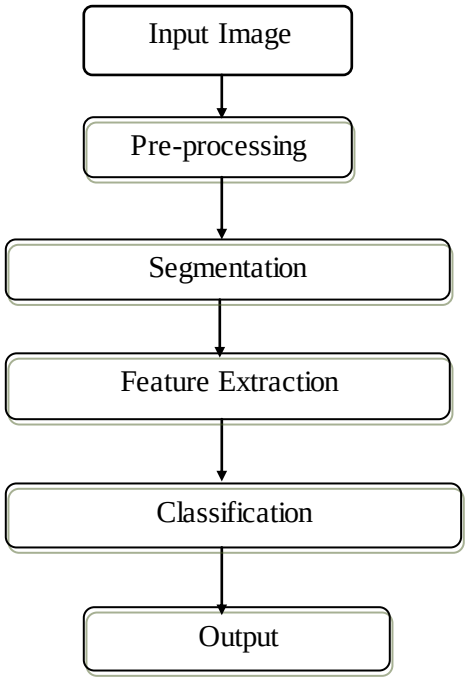

Fig.1: Flow Diagram of Nodule Classification

2.1 Input Image: US images are used as input to classify the benign and malignant nodules, we used 7 benign and 2 malignant nodules images of different patients which are

DICOM in nature. These images are set of B-mode images obtained from Philips HD11XE, 3-12MHz frequency, and are provided by HCG cancer center, Kalaburgi These images are labeled by the expert radiologist.

2.2 Pre processing: In this we are going resize the input image. Nearest-neighbor interpolation is one of the simpler way of resizing image. In nearest-neighbor interpolation if we replace every pixel with multiple pixels of the same colors, the resulting image is larger than the original, and preserves all the original detail. For decreasing image size we are going to remove multiple pixels from same colors, the resulting image is smaller then original image [6].

2.3 Segmentation of thyroid nodule: Segmentation is the process of partitioning a input image into multiple segments, The goal of segmentation is to change the representation of an image into something that is more meaningful and easier to analyze. The result of image segmentation is a set of segments that collectively cover the entire image, Each of the pixels in a region are similar with respect to some characteristic or computed property, such as color, intensity, or texture.

Edge detection is a part of image segmentation. It is one of the techniques for detecting intensity discontinuities in a digital image. The process of classifying and placing sharp discontinuities in an image is called the edge detection. The discontinuities are immediate changes in pixel concentration which distinguish boundaries of objects in a scene. The edge representation of an image significantly reduces the quantity of data to be processed, yet it retains essential information regarding the shapes of objects in the scene. The major property of the edge detection technique is its ability to extract the exact edge line with good orientation. Edge detection is a fundamental tool for image segmentation. Edge detection methods transform original images into edge images benefits from the changes of grey tones in the image. In image processing the edge detection treats the localization of important variations of a gray level image and the detection of the physical and geometrical properties of objects of the scene. We have many algorithms in edge detection, we are using the Canny edge detection technique, it is one of the standard edge detection techniques. It was first created by John Canny.

The algorithmic steps are as follows:

- Convolve image f(r, c) with a Gaussian function to get smooth image f^(r, c). f^(r, c)=f(r,c)*G(r,c,6)
- Apply first difference gradient operator to compute edge strength, then edge magnitude and direction are obtained.
- Apply non-maximal or critical suppression to the gradient magnitude.
- Apply threshold to the non-maximal suppression image [2].

The bellow figure shows the thyroid segmented image.

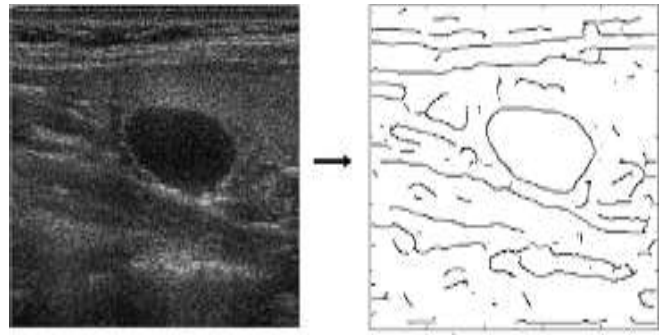

Fig.2: segmented thyroid image

2.4 Feature Extraction:

In image processing feature extraction means bringing out useful information from input image, which is relevant for solving computational task. In low level extraction the features like edge, corner and so on are detected. Even we may use shape based feature extraction by thresholding and template matching, in this we are going to extract the shapes like circles and ellipses. Normally the thyroid nodules are elliptical in shape shown in figure 3, and the nodules pixels differ from normal thyroid region hence we can use thresholding. In texture based extraction we will find following properties such as Homogeneity feature, cluster shade, contrast, entropy, energy and correlation these features are differ in normal thyroid and thyroid nodules [3]. These features are defined in below table 1.

FEATURES	EQUATIONS
Energy	$\sum_{i=0}^{N-1}\sum_{j=0}^{N-1} p(i,j)^2$
Correlation	$\sum_{i=0}^{N-1}\sum_{j=0}^{N-1} \frac{(i-\mu i)(j-\mu j)p(i,j)}{\sigma_i \sigma_j}$
Entropy	$-\sum_{i=0}^{N-1}\sum_{j=0}^{N-1} p(i,j)\log(p(i,j))$
Homogeneity	$\sum_{i=0}^{N-1}\sum_{j=0}^{N-1} \frac{p(i,j)}{1+\lvert i-j\rvert}$
Cluster Shade	$\sum_{i=0}^{N-1}\sum_{j=0}^{N-1} (i+j-\mu_x-\mu_y)^3 p(i,j)$
Contrast	$\sum_{i=0}^{N-1}\sum_{j=0}^{N-1} \lvert i-j\rvert^2 p(i,j)$
Inverse Difference Moment	$\sum_{i=0}^{N-1}\sum_{j=0}^{N-1} (1/(1+(i-j)))p(i,j)$

Table 1: Textural features

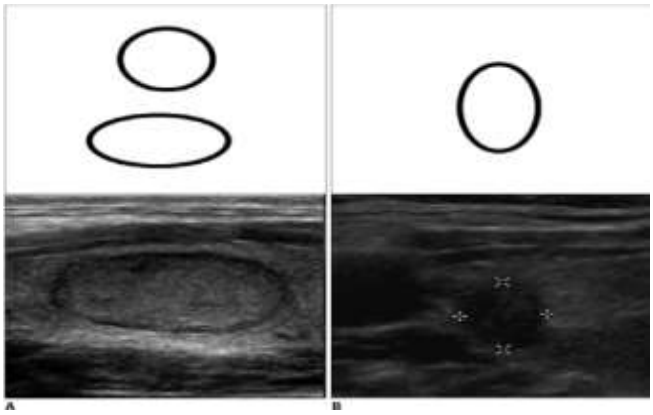

Fig.3: Shape of thyroid nodule

2.5 Classification: our main aim is to classify the thyroid nodules. We may classify based on anatomy of benign and malignant nodules as shown in bellow table 2.

Features	Benign nodule	Malignant nodule
Boundaries	Regular or encapsulated	Irregular
Size	Small	Large
Shape ellipse	Horizontal and small ellipse	Vertical and big ellipse

Table 2: difference between benign and malignant nodule

We also used artificial neural network (ANN) for better accuracy. Artificial neural networks are the collection of mathematical models that imitate the properties of biological nervous system and the functions of adaptive biological learning. It is a self learning system that changes its parameters based on external or internal information that flows through the network during the learning phase. In this work we used Back propagation neural network . It has a hidden layer with 10 neurons. [5] The neural network utilizes the texture and shape features to classify the nodule

III. THE EXPIRIMENTAL RESULTS

In this work we used 7 benign and 2 malignant nodules images we have successfully segmented the nodule and classified as shown in below images

Fig.4: Benign Part

Fig.5: Malignant Part

IV. CONCLUSION

Ultrasound imaging is widely used to inspect the nodules in thyroid gland. However, similar gray levels between thyroid benign nodule and malignant nodule can confuse the radiologists and the physicians. In addition, artifacts also degrade the quality of US images making the real shape and components of the nodules difficult to determine easily. To solve these difficulties, this paper presents a computer based method for segmenting nodules and classifying the nodules as benign or malignant. Edge detection technique is used to segment the nodule and with help an ANN classifier we have classified benign and malignant nodule.

REFERENCES

[1]. Qiang Zhang ; Yaoqi Wang ; Xianying Meng ; Renzhu Pang ; Shuai Yang "Coexistence of Medullary Carcinoma and Papillary Carcinoma in the Same Lobe of the Thyroid" A Rare Case Report Information Technology in Medicine and Education (ITME), 2016 8th International Conference on 23-25 Dec. 2016

[2]. "Edge detection techniques for image segmentation, Muthukrishnan. and M.Radha, Bharathiar University, Coimbatore, IJCSIT Vol 3, No 6, Dec 2011

[3]. R. M. Haralick, K. Shanmugam, and I. Dinstein, "Textural features for image classification," IEEE Trans. Syst.Man Cybern. Smc3, 610–621, 1973.

[4]. Xiaofeng Yang, Srini Tridandapani, Jonathan J. Beitler and David S. Yu, Emi J. Yoshida, Walter J. Curran and Tian Liu. "Ultrasound GLCM texture analysis of radiation-induced parotid-gland injury in head-andneck cancer radiotherapy: An in vivo study of late toxicity", Med. Phys. 39 (9), 5732-5739, 2012.

[5]. Thyroid Nodule Segmentation and Classification in Ultrasound Images. Gireesha H M, Nanda S, International Journal of Engineering Research & Technology (IJERT), ISSN: 2278-0181, Vol. 3 Issue 5, May – 2014.

[6]. An Efficient Algorithm for Image Scaling with High Boost Filtering, Safinaz.S Asst.Professor, Dept of ECE, Sir MVIT, Bangalore, International Journal of Scientific and Research Publications, Volume 4, Issue 5, May 2014