

Toxicological Assessment of Synergistic Efficacy of *Alstonia boonie* & *Capsicum frutescens* Extract on *Plasmodium berghei* (NK 65) / *Salmonella typhi* (ATCC 35723) Infected Swiss Albino Mice

Oludare Temitope Osuntokun & Pius John Ajiga

Department of Microbiology, Faculty of Science, Adekunle Ajasin University, Akungba, Akoko, Ondo State, Nigeria

Abstract:-Malaria and typhoid is one of the most killing diseases in the world particularly in tropical countries and is worst in Africa. The study was conducted to determine the anti-malaria/anti-typhoid potentials of graded doses coupled with the toxicological and histo-pathological effect of synergistic aqueous and ethanolic extract of *Alstonia boonie* Stem bark (Epo ahun) and fruit of *Fruit of Capsicum frutescens* in Swiss albino mice infected with *Plasmodium berghei* NK65 and *Salmonella typhi*(ATCC 35723). The stem bark *Alstonia boonie* Stem bark and fruit of *Capsicum frutescens* were screened for the presence of some qualitative screening of Secondary metabolite (phytochemicals). Twenty five (25) Swiss Albino mice were divided into 5 groups (Group 1A, 2B, 3C, 4D and 5E) of 5 mice each. The animal were inoculated with the parasite (*Plasmodium berghei* (Nk 65) and *Salmonella typhi*(ATCC 35723). At the beginning of the experiment (day 10). Three hours after inoculation (infestation 0 groups 1-3), the Swiss albino mice were respectively given 100, 200 and 400 mg combined extract/kg body weight dose intraperitoneally. Group 4D test animals which serve as control were given 5 mg Chloroquine/ Ciprofloxacin kg body weight while the group 5 animals (negative control) were given 0.2ml distilled water. The treatment was given once per day for four days. On the 5th day, the test animal caudal and vein samples were taken and transferred into a slide making thin film from each Swiss albino mouse. The percentage chemo-suppressive activity on early malaria and typhoid infection in Swiss albino mice of 100, 200, and 400 mg/kg body weight dose were found to be 81, 85, 75 respectively for ethanolic extract and 57, 78 and 80% respectively. For Aqueous extract, this is substantial when compared to 97% chemo-suppressive effect produced by Swiss albino mice 5 mg/kg body weight of Chloroquine/Ciprofloxacin. The Secondary metabolite (phytochemical) screening of the combined extract reveals the presence of Saponins, Flavonoids, Terpenes, Alkaloids, Glycosides, Terpenoids while anthroquinones and acid compounds were found absent. The acute toxicity (LD₅₀) of the combined extract was estimated to be 3162 mg kg⁻¹ body weight. The above result showed that the combined extract of Stem bark of *Alstonia boonie* and fruit of *capsicum frutescens* possesses antiplasmodal and anti-typhoid potentials. The toxicological and histopathological study of the synergistic extract of *Alstonia boonei* and *fruit of Capsicum frutescens* were studied with observable features in the liver enzymes and kidney function on slide after staining. The results from this findings shows an increase in the serum Alanine amino-transaminase(ALT), Aspartate amino-transaminase (AST), Alkaline phosphatase

(ALP), Bilirubin, Blood Urea Nitrogen (BUN) and Creatinine level of the liver and kidney of the infected Swiss Albino Mice were normal. which signifies that the organs were not affected by the administration of the medicinal plants. This dose dependent increase is an indication of low toxicity of the extract which calls for a moderate use of the extract.

Keywords - Anti-Malaria/Anti-Typhoid, Toxicological Assessment, Synergistic Extract *Alstonia Boonie*, *Capsicum frutescens*, Swiss Albino Mice.

I. INTRODUCTION

Alstonia boonie, among other plants, has been noted as a good medicinal plant for curing various diseases. *Alstonia.boonei* which belongs to the Apocynaceae family have severally been reported to have medicinal properties. As such, they are used by traditional health practitioners especially in rural areas. Several species of *Alstonia boonie* abound including *Alstonia macropylla*, *Alstonia scholaris* etc. But this species are not as popular as *Alstonia boonei*, which have been widely reported in Nigeria. Typically, *Alstonia boonei* is a facultative plant having estimated occurrence probability of 33 – 67% in both wetland and non-wetland areas. Also *Alstonia boonei* possesses therapeutic properties probably due to the presence of bioactive constituents and metabolites.

Studies have shown that *Alstonia boonei* have several medicinal properties both for human and other mammals. For instance studies has indicated that *A. boonei* have Antihyperglycemic(1). and antioxidant (2), wood healing properties (3). Others include Antiplasmodial activities against *Plasmodium berghei* infection in mice (4), Analgesic effects (5), enhancement of rotarod period in albino mice, diuretic properties in male Wistar rats (6), treatment of chronic Diarrhoea and dysentery, fever, pain, intestinal disorders and as an antidote for Strophanthus poison (7). anti-snake venom and as antidote to some arrows poisons (8), treatment of malaria, typhoid fever, gonorrhoea, yaws, asthma, dysentery, and as a galactagogue (9), and antimicrobial properties Different tissues extract of *Alstonia boonie* have been severally reported to contain some essential phytochemicals (10).

Alstonia boonie comprises about 40 species and has a pantropical distribution. There are about twelve species of the genus *Alstonia*. *Alstonia booneide* wild belongs to the family Apocynaceae. The species are scattered all over the world of which two are indigenous to Africa. The plant is known

locally in Ghana as Onyame dua, Osen-nuru, or Sinduro in twi, onyame dua in fante, sinu or adawura in ga-adangbe, bakunin, nyamenlebaka, emenle, or Emie in nzema, and Siaketekre, Nyemi dua, or asi atoe in ewe (11).



Plate 1; showing clockwise order from top right, the leaves, stem bark of *Alstonia boonie*

Therapeutically, the stem bark has been found to possess ant rheumatic, anti-inflammatory, analgesic/pain-killing, antimalaria/antipyretic, antidiabetic (mild hypoglycaemic), antihelminthic, antimicrobial and antibiotic properties (12). *Alstonia boonie* decoction also exerts a mild antibacterial effect in this case, relieving the aches and pains associated with malaria fever. *Alstonia boonie* is taken in the form of preparations that exhibits ant pyrexia and anti-malaria effects, to combat rheumatic and arthritic pains. The decoction of *Alstonia boonie* bark could be taken alone as an effective pain-killing agent. A cold infusion made from the fresh or dried bark of *Alstonia boonie* taken orally two to three times daily exerts a mild hypoglycaemic effect on diabetic patients. *Alstonia booneidewild* is regarded as one of few herbs with potential anti-hiv indicators. In some African countries *Alstonia boonei* is considered a sacred tree and worshiped in the forest and hence human beings in those countries do not eat its parts (12).

Capsicum frutescens is a species of chili pepper that is sometimes considered to be part of the species *K. Pepper* cultivars of *C. frutescens* can be annual or short-lived perennial plants. Flowers are white with a greenish white or greenish yellow corolla, and are either insect- or self-pollinated. The plants' berries typically grow erect; ellipsoid-conical to lanceoloid shaped. They are usually very small and pungent, growing 10–20 millimeters (0.39–0.79 in) long and 3–7 millimeters (0.12–0.28 in) in diameter. (Y) Fruit typically grows a pale yellow and matures to a bright red, but can also be other colors. *Capsicum frutescens* has a smaller variety of shapes compared to other *Capsicum* species. *Capsicum frutescens* has been bred to produce ornamental strains, because of its large quantities of erect peppers growing in colorful ripening patterns.

Plate 2 : Picture of Fruit of *Capsicum frutescens*

The prevalence of malaria/ typhoid fever as well as growing incidence of the death resulting from the disease coupled with the increase in the resistance of malaria parasite and *Salmonella typhoid* to synthetic drugs has led to the increase search for alternative treatment strategy(12).

Plants are cheap sources of medicinal intervention both for curative and preventive measures in Africa and Asia Continents, a greater percentage of the world population solely depend on medicinal plants; hence need to carry out researches on the particular dosage needed to suppress the ailment. The synergistic ethanolic extract of *Alstonia boonei* and fruit of *Capsicum frutescens* has been scientifically screened to contain certain phytochemicals which are responsible for the prevention or treatment of malaria parasite and *Salmonella typhi* and with acute toxicity which may be unknown to some individuals. The present study is thus necessary to fill the lacuna as it establishes the curative power and toxic effect of the synergistic extract on the treatment malaria and typhoid (13).

II. MATERIALS AND METHOD

2.1 Apparatus

The apparatus used include beaker, conical flasks, measuring cylinders, weighing balance, universal centrifuge and volumetric flasks. Thermometer, glass pipette, syringes and needle, test tubes and racks, spatula, glass rod, reagent bottles, water bath, UV-visible spectrophotometer, dissecting board, dissecting set, sample bottles, funnel, oral intubator (cannular), PH meter, microscope, gloves, -20°C and -80°C refrigerator, kidney function and liver function kits, , , petri-dishes,

2.2 Reagents

Washing buffer (1.15% chloride) 1.15g of potassium chloride (BDH chemical limited, England) was dissolved in 100ml distilled water and made up to 1000ml and stored at 4°C homogenizing buffer (0.1m Phosphate buffer, PH. 7.4)

(a) 11.8g of Na_2HPO_4 (sigma chemical co. St. Louis U.S.A.) was dissolved in 1000ml distilled water.

(b) 6.8g of KH_2HPO_4 was dissolved in 500ml distilled water, then 800mls of (a) was mixed with 200ml of (b) above to make 1000ml. The PH. was adjusted to 7.4 with 1m NAOH. This was then stored at 4°C till use.

2.3 Plant Samples Identification

The *Alstonia boonei* and *Capsicum frutescens* were identified based on the description provided by Dr. OBEMBE of Plant Science And Biotechnology Department, Adekunle Ajasin University Akungba Akoko. Some of the description includes a large deciduous evergreen tree that could reach 45m tall and 1.2 m in diameter, deeply fluted to 7 m, small buttresses greyish-green or grey for the bark, milky latex from the leave and bark and 5 – 7 whorls of leaves. The plant has several english name including stool wood, Cheesewood, pattern wood, *Alstonia boonei*.

2.4 Collections of Plant Samples

The Stem bark of *Alstonia boonei* and *Capsicum frutescens* used in this study were collected early in the morning around 6.30am from within Adekunle Ajasin University, Akungba Akoko, Nigeria premises.

2.5 Plant Samples Preparation

The collected stem bark of *Alstonia boonei* and *Capsicum frutescens* were washed with water and screened for foreign object and to get rid of dirt after which it was air dried for

about four weeks and grounded into fine powder under aseptic conditions. Using a mechanical grinder; about 1kg of *Alstonia boonie* and 300g of *Capsicum frutescens* powder were weighed into 500 ml of 80% ethanol and 25% water, in a bottle which was covered air tight. The solutions were filtered using Whatman No 1, filter paper. The filtrates were evaporated to dryness using a rotary evaporator and stored at 4 °C until required for uses (13, 14).

2.6 Parasites Used

The *Plasmodium berghei* (Nk 65) was obtained from Institute of Medical Research and Training (IAMRAT) College of Medicine, University of Ibadan, Oyo State, Nigeria. A standard inoculum of 1×10^7 of parasitized erythrocytes from a donor mouse in volume of 0.2ml was used to infect the experimental animals intra-peritoneally.

2.7 Organism Used

Salmonella typhi (ATCC 35723) was used for this research work. It was obtained from (IAMRAT) College of Medicine, University of Ibadan, Oyo State, Nigeria. A standard inoculum of 2×10^8 acetone-killed *Salmonella typhi* with the vi antigen-free variant 0-901 was used to infect the Swiss Albino mice intra-peritoneally.

2.8 Experimental Test Animal

Swiss albino mice between 15-20g obtained from animal house, IAMRAT, College Of Medicine, University of Ibadan, Oyo state, Nigeria.

2.9 Acute Toxicity Studies (LD_{50})

The median lethal dose (LD_{50}) of the synergistic extract of *Alstonia boonie* Stem bark and *Capsicum frutescens* fruit at 60/40 percentile that will kill 50% of the animals in a population was determined intra-peritoneally using the method described by (15). The mice were divided into five groups of four mice each weighing between 13-23g. The mice were subjected to 24 h fasting (with only water) before administration of the synergistic extracts. The extract was dissolved in 20% Tween-80 and administered in doses of 500, 1,000, 2,000, 3,000 and 4,000 mg kg⁻¹ b.wt. intra-peritoneally. The sixth group served as the control and received only 20% Tween-80. The mice were then observed for toxicity and fatalities over 72 h (40,15).

The LD_{50} was calculated using the equation of Lorke (1983):

Where: SQUARE ROOT OF A and B

a = Least tolerable dose

b = Maximum tolerable dose

2.10 Administration Of Extracts:

The mice parasitized with *Plasmodium berghei* (Nk 65) and *Salmonella typhi* (ATCC 35723) were sacrificed after six days, having been observed to have shown clinical symptoms

of malaria and typhoid fever. The mice were anaesthetized in a glass jar containing cotton wool soaked in chloroform. Blood was collected from the sacrificed mice by cardiac puncture using sterile syringes and needles. The blood was diluted in normal saline in the ratio of 1:10 (1 mL of blood in 10 mL of normal saline). The organism and parasitized Erythrocyte in volume of 0.3 mL was used to infect each of the experimental mice intra-peritoneally six days before treatment (16).

2.11 Test For Anti-Malaria/Anti-Typhoid Activity

The suppressive antimalarial test, known as "Test on Early Malaria Infection" as reported by (17) was used in this study. For the Ethanolic and Aqueous extracts (separately), 25 mice were divided into 5 groups of five mice each. The animals were inoculated with the parasite/organism at the beginning of the experiment (day 10). Three hours after inoculation (infestation 0 groups 1-3 mice were respectively given 100, 200, and 400 mg extract/kg body weight dose orally, group 4 animals, which served as positive control were given 5 mg chloroquine/ Ciprofloxacin kg body weight while the group five animals (negative control) were given 0.2 ml distilled water. The treatment was given once per day for four days. On the 5th day, two drops of the animals caudal vein blood samples were taken and transferred on slides – making thin film from each mouse. The slides were stained with Giemsa stain and subjected to microscopy. The average percentage parasitaemia/typhoidal and hence percentage chemo-suppression were evaluated for each of the does using the formulae: % Suppression = (Average parasitaemia in negative control – Average parasitaemia/typhoidal (in test dose)/Average parasitaemia/typhoidal in negative control) × 100 (17).

2.12 Tissue Histopathology

The fixed liver and kidney tissues were dehydrated by ascending grades of isopropyl alcohol for an hour. The dehydrated organs were cleared in xylene and transferred into two changes of liquid paraffin wax. The tissue sections were stained in Ehrlich's hematoxylin for 8 minutes, washed in water and dipped in acid alcohol to remove excess stain. These were counter stained in 10% aqueous eosin, incubated and mounted for photomicrography (18)

2.13 Phytochemical Screening Of *Alstonia Boonie* And *Capsicum Frutescens*

The secondary metabolite (phytochemical) screening of the sample was carried out as described by (18). The samples were screened for the following components.

Test For Saponins: To 1 ml of plant extract, 5-10 ml of distilled water was added and shaken in a graduated cylinder for 15 minutes lengthwise. Formation of 1cm layer of foam indicates the presence of Saponins.

Test For Flavonoids: A fraction of the extract was treated with concentrated sulphuric acid and observed for the formation of orange color.

Test For Alkaloids: To 2 ml of plant extract, 2 ml of concentrated hydrochloric acid was added. Then few drops of Mayer's reagent were added. Presence of green color or white precipitate indicates alkaloids.

Test For Glycosides: To 2 ml of plant extract, 1 ml of glacial acetic acid and 5 % ferric chloride was added. Then few drops of concentrated sulphuric acid were added. Presence of greenish blue color indicates glycosides.

Test For Terpenoids And Steroids: A fraction of the extract was dissolved in chloroform. A few drops of acetic anhydride were added followed by two drops of conc. H₂SO₄. Reddish –pink colouration indicates terpenoids and steroids.

Test For Carotenoids: To about 2ml of the extract, 3ml of antimony trichloride was added. Dark-blue colouration is indicative of carotenoids.

Test For Coumarins: A small quantity of plant extract was taken into a test-tube. The test-tube was then covered with a piece of filter paper moistened with dil. NaOH solution and placed in a hot water bath. After about 15 minutes, the paper was removed and exposed to U.V light. Yellow-green fluorescence indicates the presence of coumarins.

Test For Anthraquinones: A small amount of the extract was boiled with 25 ml of 0.5M KOH and 4 ml of H₂O₂. The mixture was then cooled and acidified with a few drops of acetic acid. The acidulated mixture was extracted with a small amount of benzene (15ml). The benzene extract was shaken with a small amount of NH₄OH. Red colouration indicates anthraquinones. Colourless alkaline layer indicates absence of anthraquinones.

Test For Anthraquinone Glycosides: To about 2ml of the extract, 20 ml of dilute H₂SO₄ was added and boiled. The mixture was filtered hot and a portion of the cooled filtrate was shaken with an equal volume of benzene. The benzene layer was separated and shaken with about half its volume of dilute NH₃ solution. A colourless ammoniacal layer indicates the absence of anthraquinone glycosides.

Test For Cyanogenetic Glycosides: To about 2ml of the extract was taken into a test-tube. A few drops of chloroform was then added and a piece of moist sodium picrate paper was inserted into the test-tube, taking care that it does not come into contact is kept warmed at 35°C for about 3 hours. The presence of red colour of the sodium picrate paper after the 3 hours indicates cyanogenetic glycosides.

2.14 Biochemical Assay

Serum biochemical parameters Alanine transaminase (ALT), Aspartate transaminase (AST) Alanine phosphates (ALP), Bilirubin, Blood urea Nitrogen and Creatinine were estimated using commercial kit. Preparation of tissue homogenate and

blood collection for biochemical analyses. The animals were sacrificed on the 24 hours after the administration of the last treatment, i.e. Second day; three rats were sacrificed from each group while blood samples, liver and kidney were obtained for biochemical analysis and histopathology. The blood samples were then centrifuged for 10 minutes at 3,000g using bench centrifuge. The supernatant (serum) was collected and serum Alanine aminotransaminase (ALT), Aspartate aminotransaminase (AST), Alkaline phosphatase (ALP), Bilirubin, Blood Urea Nitrogen (BUN) and Creatinine were determined (19).

2.15 Statistical Analysis

The results were expressed in terms of mean \pm standard deviation (sd). Parameters in the groups were compared by one-way (Anova) using SPSS version 15. Significant differences were set at ($p < 0.05$).

III. RESULT AND DISCUSSION

TABLE 1: The results of the secondary metabolite (phytochemical screening) of Stem bark of *Alstonia boonie* showing the presence of Alkaloids, Tannins, Saponins, Steroids, Flavonoids and Cardiac Glycosides in substantial quantities. Anthroquinones and Acid compounds were however not detected in the stem bark of *Alstonia boonie*. The presence of alkaloids in high concentration in the stem bark of *Alstonia boonie* explains the traditional use of the plant for the treatment of malaria. The medicinal plants that are moderately rich in alkaloids and tannins have potential health promoting effects.

TABLE 2: showing the results of the secondary metabolite (phytochemical) screening of *Capsicum frutescens*, it shows the presence of Alkaloids, Tannins, Saponin, steroids, flavonoids, Carotenoids, Terpenoids, while Anthroquinones, Glycosides and Acid compounds was not detected..

TABLE 3: shows the effects of Ethanolic extract of *Alstonia boonei* Stem bark powder on early infection in Swiss albino mice. The in-vivo evaluation revealed that the average percentage suppression of parasitaemia/typhoid by the extract was 81, 85 and 75% at doses of 100, 200 and 400 mg/kg body weight per day, respectively.

TABLE 4: on the other hand, portrays the effect of the Aqueous extract on the same early malaria/typhoid infection. From the table, the average percentage suppression of parasitaemia/typhoidal was 56, 78 and 80% at doses of 100, 200 and 400 mg/kg/day, respectively. Chloroquine/Ciprofloxacin, under the same experimental condition, at 5 mg/kg body weight per day produced chemosuppression of 97%.

TABLE 5: Effect of synergistic acute administration of extracts *Astonia boonie* and *Capsicum frutescens* at 60/40 percentile on liver enzymes which include the Alanine transaminase (ALT), Aspartate transaminase (AST) Alanine phosphates (ALP). Distilled water of 10ml/kg was used as a

control on the liver enzymes, after which a dose of the synergistic extract ranging from (1000, 2000, and 4000) mg/kg is used. The result shows a high variation when 2000mg/kg of the synergistic extract was used which later reduce at 4000mg/kg dose.

The histological photograph of the liver enzymes taken at each dose was stained and viewed under microscope (He x400):

GROUP 1A distilled water (10ml/kg) -there is no observable lesion.

GROUP 2B synergistic extract (1000mg/kg)- - there is moderate atrophy of hepatic cords and accentuation of sinusoids (arrows)

GROUP 3C synergistic extract (2000mg/kg)- There is centrilobular hepatocellular generation, necrosis (blue arrow) and inflammation (black arrow)

GROUP 4D synergistic extract (4000mg/kg)- There is centrilobular hepatocellular generation, necrosis (blue arrow) and inflammation (black arrow).

GROUP 5E – Control

Table 6: Effect of acute administration of synergistic extract of *Alstonia boonie* and *Capsicum frutescens* at 60/40 on kidney function test. A group of swiss albino mice were treated with distilled water as control experiment. The kidney functional test was carried out on the Bilirubin, Blood Urea Nitrogen and Creatinine. There is a noticeable increase in the kidney activity on administration of the synergistic Ethanolic extract when compared to the kidney function when extracts are not utilized.

The histological photograph of the kidney function taken at each dose was stained and viewed under microscope (He x400).

GROUP 1A Distilled water (10ml/kg) - There is moderate interstitial capillary congestion (arrows)

GROUP 2B: Synergistic extract (1000mg/kg)- There is tubular epithelial coagulation necrosis (arrow) and attenuation.

GROUP 3C: Synergistic extract (2000mg/kg)- There is patchy tubular epithelial coagulation necrosis (arrows) and attenuation.

GROUP 4D: Synergistic extract (4000mg/kg)-There is tubular epithelial coagulation necrosis (arrows) and luminal Ectasias

GROUP 5E – Control

TABLE 2 & 3 :The qualitative Secondary metabolite (phytochemical screening) of *Alstonia boonie* (Stem bark) & *Capsicum frutescens* (fruit)

| Secondary metabolite | <i>Alstonia boonie</i> (Stem bark) | <i>Capsicum frutescens</i> (Fruit) |
|----------------------|------------------------------------|------------------------------------|
| Alkaloids | +ve | + ve |
| Tannins | + ve | + ve |
| Saponins | + ve | + ve |
| Anthroquinones | - ve | - ve |
| Steroids | + ve | + ve |
| Terpenoids | + ve | + ve |
| Flavonoids | + ve | + ve |
| Glycosides | + ve | - ve |
| Acid compounds | - ve | - ve |

Key: + present, –absent

TABLE 3: Effect of Ethanolic extract of *Alstonia boonie* (stem bark (60%) and *Capsicum frutescens* (Fruit,40%) on early malaria/typhoid infection in Swiss Albino Mice

| Treatment | Dose concentration (mg/kg/day) | Average suppression* | Percentage suppression(%) |
|--|--------------------------------|----------------------|---------------------------|
| Extract- <i>Alstbo stb</i> (60%)& <i>Capfr</i> (40%) | 100 | 10.20±0.86 | 81 |
| Extract- <i>Alstbo stb</i> (60%)& <i>Capfr</i> (40%) | 200 | 8.00±0.77 | 85 |
| Extract- <i>Alstbo stb</i> (60%)& <i>Capfr</i> (40%) | 400 | 13.75±3.12 | 75 |
| Chloroquine/Ciprofloxacin | 5 | 1.60±0.24 | 97 |
| Distilled water | 0.2 ml | 54.40±4.45 | 0 |

Key- Extract -*Alstonia boonie* stem bark (60%) and *Capsicum frutescens*(40%)

Figure 1; shows the Percentage suppression of Ethanolic extract of *Alstonia boonie* stem bark (60%) and *Capsicum frutescens*(40%) on early malaria/typhoid infection in Swiss Albino Mice (%).

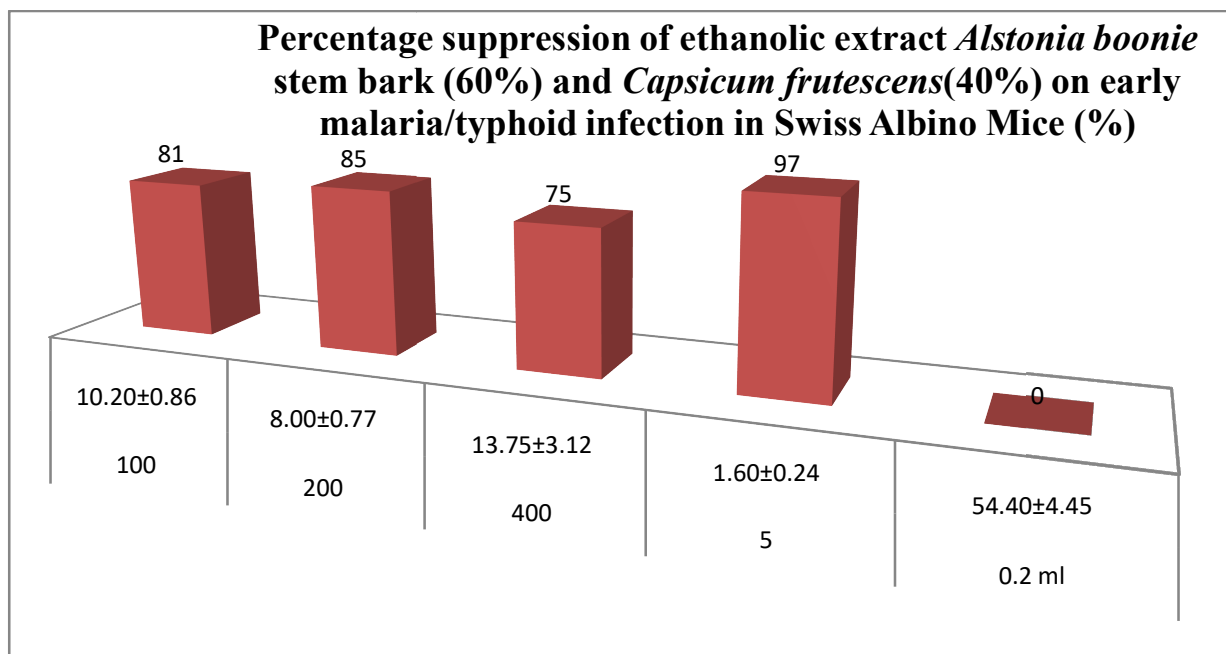


TABLE 4: Effect of Aqueous extract of *Alstonia boonie* stem bark (60%) and *Capsicum frutescens* (40%) on Malaria/typhoid infected Swiss Albino mice

| Treatment | Dose concentration (mg/kg/day) | Average suppression* | Percentage suppression |
|--|--------------------------------|----------------------|------------------------|
| <i>Alstbostb</i> (60%) & <i>Capfr</i> (40%) | 100 | 25.00±0.5 | 56 |
| <i>Alstbo stb</i> (60%) & <i>Capfr</i> (40%) | 200 | 12.20±2.25 | 78 |
| <i>Alstbostb</i> (60%) & <i>Capfr</i> (40%) | 400 | 11.50±2.72 | 80 |
| Chloroquine/ Ciprofloxacin | 5 | 1.60±0.24 | 97 |
| Distilled water | 0.2 | 54.40±4.45 | 0 |

Figure 2; shows the Percentage suppression aqueous extract of *Alstonia boonie* stem bark (60%) and *Capsicum frutescens* (40%) on Malaria/typhoid infected Swiss Albino mice.

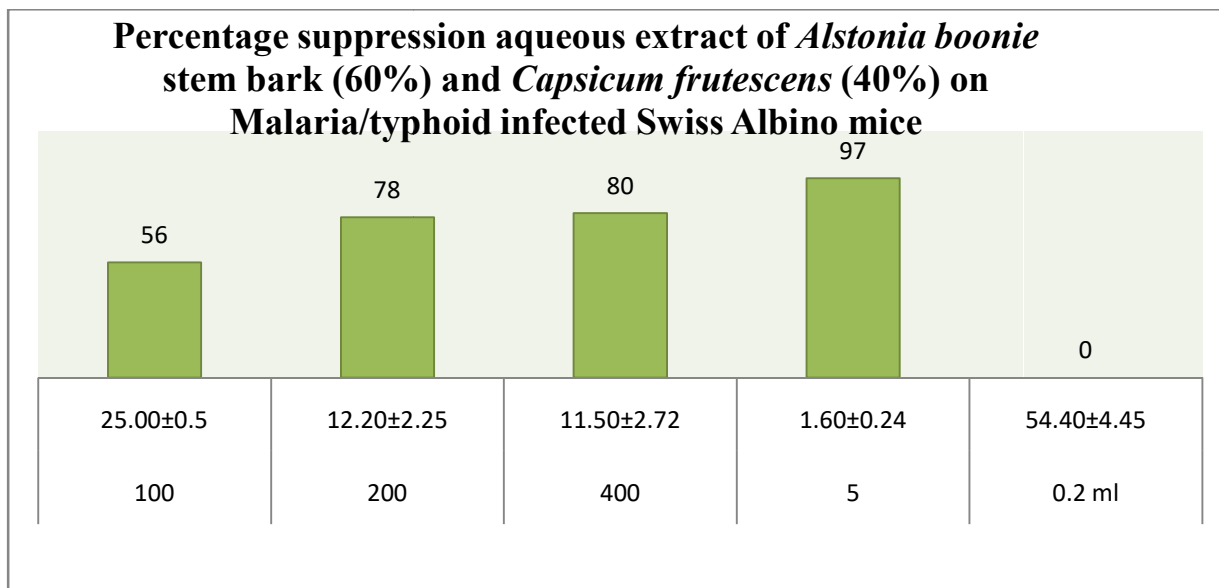


TABLE 5: Effect of acute administration of *Alstonia boonie* (60%) and *Capsicum frutescens* (40%) on liver enzymes

| GROUP | DOSE CONCENTRATION | AST(u/l) | ALT(u/l) | ALP(u/l) |
|-------|--|-------------------------|-------------------------|------------------------|
| 1 | Distilled water 10ml/kg | 43.45±0.3 | 43.45±0.4 | 29.11±2.1 |
| 2 | Synergistic extract (<i>Alstbostb</i> (60%) & <i>Capfr</i> (40%) 1000 mg/kg | 46.07± 0.1 | 57.52±1.2 | 33.02±1.2 |
| 3 | Synergistic extract(<i>Alstbostb</i> (60%) & <i>Capfr</i> (40%) 2000 mg/kg | 131.02±1.1 [*] | 140.44±0.1 [*] | 84.21±0.3 [*] |
| 4 | Synergistic extract <i>Alstbostb</i> (60%) & <i>Capfr</i> (40%)4000 mg/kg | 86.90±0.21 [*] | 86.90±1.3 [*] | 67.32±2.1 [*] |

Key- Extract -*Alstonia boonie* stem bark (60%) and *Capsicum frutescens*(40%)

*p<0.05= significant when compared with distilled water, where(AST) means Assay of aspartate aminotransferase, (ALT) Assay of alanine amino transferase, Alkaline phosphate

Table 6: Effect of acute administration of *Alstonia boonie* and *Capsicum frutescens* on kidney function test

| GROUP | DOSE CONCENTRATION | Bilirubin (mg/dl) | Bun (mg/dl) | Crt (mg/dl) |
|-------|--|-------------------|-------------|-------------|
| 1 | Distilled water 10ml/kg | 1.95±1.2 | 11.90±0.3 | 1.80±0.1 |
| 2 | Synergistic extract (<i>Alstbostb</i> (60%) & <i>Capfr</i> (40%) 1000 mg/kg | 2.16±0.2 | 12.45±0.4 | 1.80±2.2 |
| 3 | Synergistic extract(<i>Alstbostb</i> (60%) & <i>Capfr</i> (40%) 2000 mg/kg | 3.50±1.1 | 12.50±1.3 | 2.00±1.2 |
| 4 | Synergistic extract <i>Alstbostb</i> (60%) & <i>Capfr</i> (40%)4000 mg/kg | 2.50±0.1 | 12.86±1.0 | 2.20±0.3 |

KEY: (BUN) = Blood Urea Nitrogen, (CRT) = Creatinine

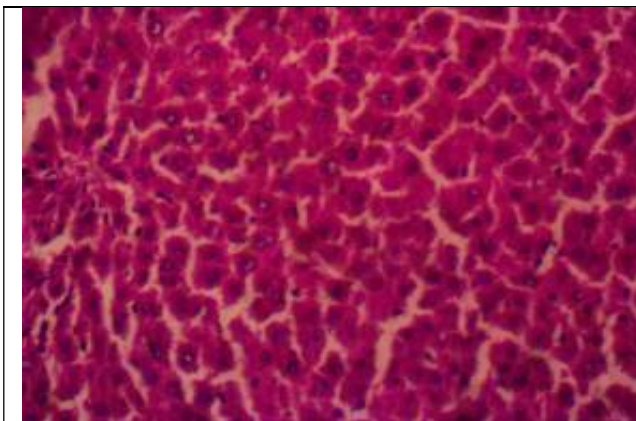


Figure 3; Distilled water 10ml/kg -there is no observable lesion. He x400

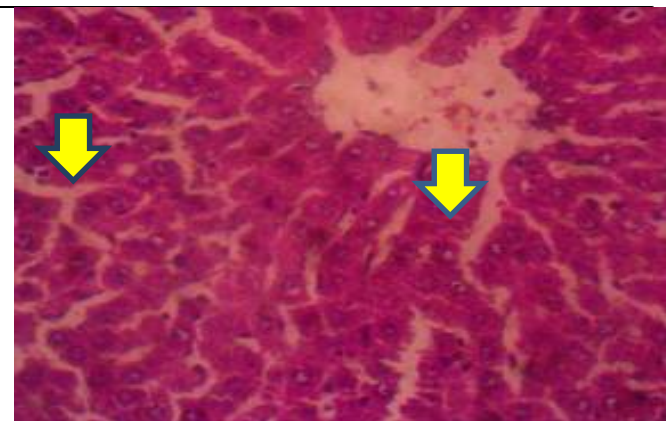

Figure 4; *Alstonia boonei* *Capsicum frutescens* (1000mg/kg)-there is moderate atrophy of hepatic cords and accentuation of sinusoids (arrows). He x400

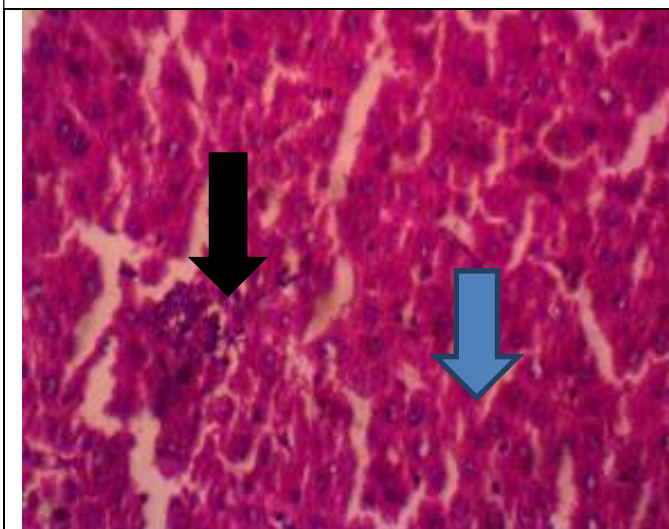


Figure 5; *Alstonia boonei* and *Capsicum frutescens* (2000mg/kg) - There is centrilobular hepatocellular generation, necrosis (blue arrow) and inflammation (black arrow). HE x400

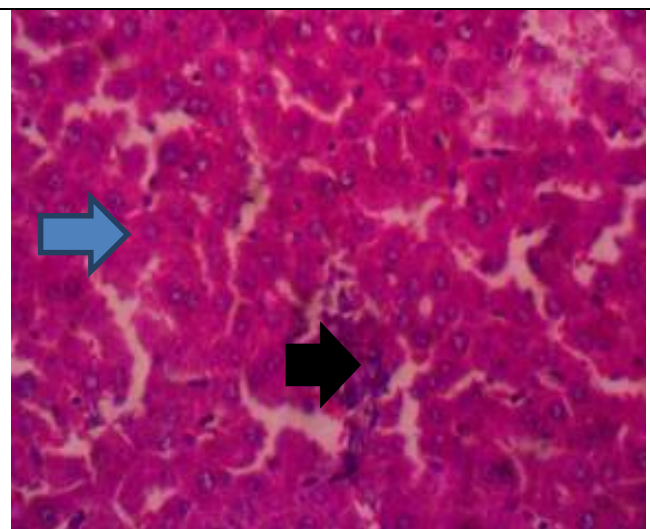


Figure 6; *Alstonia boonei* and *Capsicum frutescens* (4000mg/kg) - There is centrilobular hepatocellular generation, necrosis (blue arrow) and inflammation (black arrow). HE x400

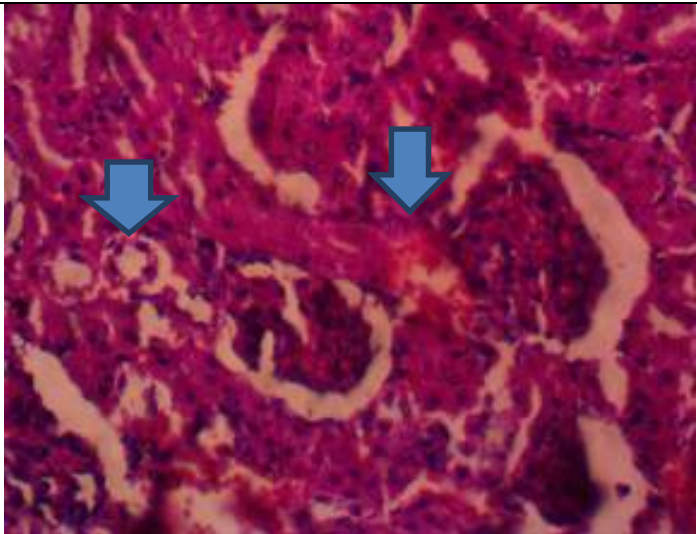


Figure 3b; Distilled water 10ml/kg - There is moderate interstitial capillary congestion (arrows). HE x400

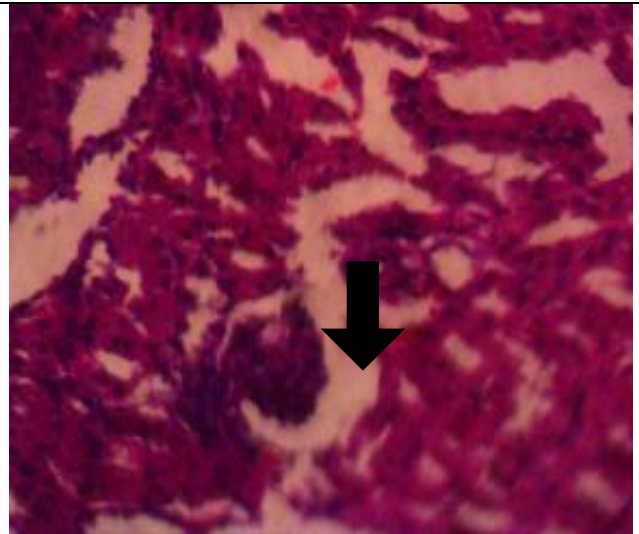


Figure 7; *Alstonia boonei* and *Capsicum frutescens* (1000mg/kg)- There is tubular epithelial coagulation necrosis (arrow) and attenuation. HE x400

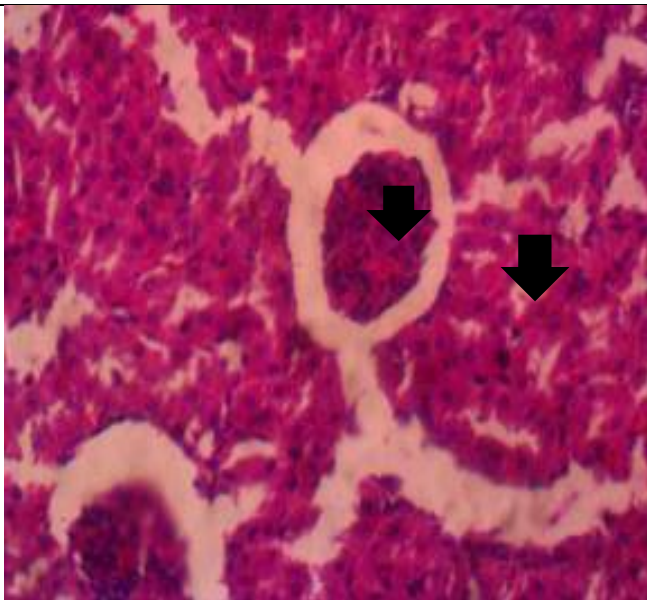


Figure 8; *Alstonia boonei* and *Capsicum frutescens* (2000mg/kg)- There is patchy tubular epithelial coagulation necrosis (arrows) and attenuation. HE x400

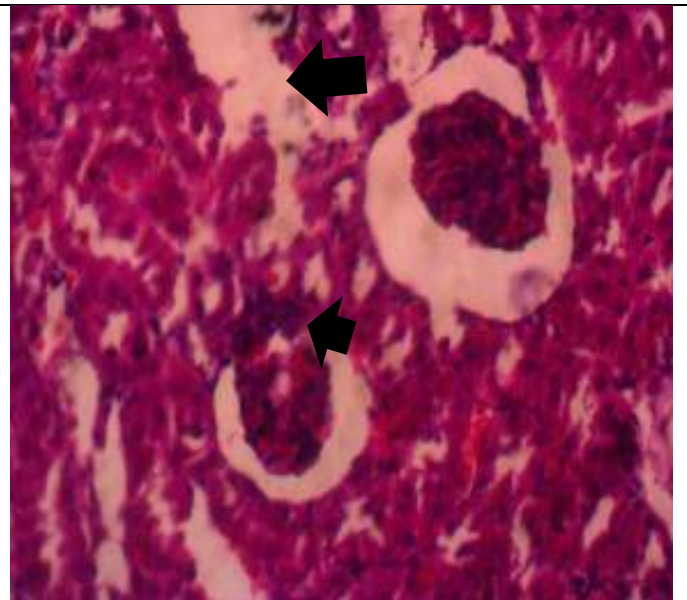


Figure 9; *Alstonia boonei* and *Capsicum frutescens* (4000mg/kg) - There is tubular epithelial coagulation necrosis (arrows) and luminal Ectasia. HE x400

KEY:

FIGURE 3a and 3b: Showing the histopathological result of acute administration of *Astonia. boonei* on liver (Distilled water 10ml/kg), Distilled water 10ml/kg -there is no

observable lesion and There is moderate interstitial capillary congestion (arrows). HE x400.

Figure 4; *Alstonia boonei* *Capsicum frutescens* (1000mg/kg) - there is moderate atrophy of hepatic cords and accentuation of sinusoids (arrows). He x400

FIGURE 5: Showing the histopathological result of acute administration of *Astonia boonei* on liver (*A. boonei* 2000mg/kg). *Alstonia boonei* and *Capsicum frutescens* (2000mg/kg) - There is centrilobular hepatocellular generation, necrosis (blue arrow) and inflammation (black arrow). HE x400

FIGURE 6: Showing the histopathological result of acute administration of *Astonia boonei* on liver (*Alstonia boonei* 4000mg/kg). *Alstonia boonei* and *Capsicum frutescens* (4000mg/kg) - There is centrilobular hepatocellular generation, necrosis (blue arrow) and inflammation (black arrow). HE x400

Figure 7; *Alstonia boonei* *Capsicum frutescens* (1000mg/kg) - there is moderate atrophy of hepatic cords and accentuation of sinusoids (arrows). He x400, *Alstonia boonei* and *Capsicum frutescens* (1000mg/kg)- There is tubular epithelial coagulation necrosis (arrow) and attenuation. HE x400

FIGURE 8: Showing the histopathological result of acute administration of *Astonia boonei* and *Capsicum frutescens* on liver (2000mg/kg). *Alstonia boonei* and *Capsicum frutescens* (2000mg/kg) - There is patchy tubular epithelial coagulation necrosis (arrows) and attenuation. HE x400

Figure 9: Showing the histopathological result of acute administration of *Astonia boonei* on kidney (*Alstonia boonei* 4000mg/), *Alstonia boonei* and *Capsicum frutescens* (4000mg/kg) - There is tubular epithelial coagulation necrosis (arrows) and luminal Ectasia. HE x400

IV. DISCUSSION

This study evaluates the toxicological assessment of synergistic extract *Alstonia boonei* & *Capacium frutescens* extract on *plasmodium berghei* (NK 65) / *Salmonella typhi* (ATCC 35723) infected Swiss Albino mice. It also evaluates the antimalarial/anti-typhoid activity of Ethanolic and Aqueous Stem bark of *Alstonia boonei* and *Capsicum frutescens* coupled with toxicological effect on the liver and kidney of Swiss Albino Mice.

Currently no single synthetic drug was effective for treating multi-drug resistant malaria/ typhoid, effective combination therapy includes Artemisinin derivatives such as Artesunate (19), or mixtures with older drugs such as the atovaquone (19) Proguanil (20) combination Malarone (21). Unfortunately first reports on drug resistance to Artemisinin-derivatives (22) and to drug combination therapies (23) have already appeared. This shows a greater needs to synergize two or more plants with different secondary metabolites (phytochemical constituents), to treat infection and diseases.

In the absence of a functional, safe and widely available malaria/typhoid vaccine, efforts to develop new ant malarial/anti-typhoid drugs continue. There has been a consensus among the scientific community that natural products have been playing a dominant role in this discovery that has leads to the development of new drugs for the

treatment of human diseases (24). Indeed, the vast majority of the existing anti-malarial/anti-typhoid chemotherapeutic agents are based on natural products and this fact anticipates that new leads may certainly emerge from the tropical plant source. Biological chemo-diversity continues to be an important source of molecular templates in the search for anti-malarial drugs (25).

The secondary metabolites (phytochemical) screening of Stem bark of *Alstonia boonei* and *Capsicum frutescens* fruit shows the presence of Tannins, Flavonoids, Resins, Saponins, Terpenes, Alkaloids, Glycosides while Anthraquinones and acid compounds are absent in the both plants. Similar results were recorded by (25), (6). These constituents have been found in other natural products which exhibited antimalarial activity (26) reported that plants which contain many secondary metabolites with biological activities like alkaloids and flavonoids could serve as sources of antimalarial drugs. Studies have recorded that some of these secondary metabolites compounds are antioxidants. This property of the plants has been implicated in creation of an intracellular environment that is unfavourable to plasmodial/*salmonella typhi* growth (27). This suggested that the antiplasmodial/anti-typhoidal properties of the synergistic extract could be based on the antioxidant, antiparasitic and antimicrobial effects of these secondary metabolites(28). This observation is validated by (29) who reported that Artemisinin/Ciprofloxacin(a modern antimalarial/anti-typhoid drug) depends on its oxidative action for its potency against *Plasmodium* and *Salmonella* species.

These results obtained from Table 4 and 5 in agreement with (30).Shows that the plant extracts possesses antimalarial/ anti-typhoid effect. (31) reported that ethanolic Stem bark extract of *A. boonei* possesses potent antimalarial effect. (32). While the chemo-suppressive effect of aqueous extract was dose-insensitive, the ethanolic synergistic extract of *Alstonia boonei* and *Capsicum frutescens* exhibited a progressive dose-response relationship. The highest chemo-suppression (80%) observed at the highest dose (400 mg/kg/day) for aqueous extract is lower than the highest value (85%) observed at medium dose (200 mg/kg/day), for Ethanolic extract (32). This may be considered as an indication that the potency of synergistic ethanolic extract in the suppression of parasitaemia/typhoidal is more than that of aqueous extract. Relative to the value of 97% obtained for Chloroquine/Ciprofloxacin (an established anti-malaria/anti-typhoid drugs), ethanolic extract at 200 mg/kg/day effectively suppresses the infection.

The results obtained from this research using the synergistic extract is consistent with the traditional use of the plants *Alstonia boonei* and *Capsicum frutescens*, as ethnotherapeutic agent against malaria/typhoid in West and Eastern Nigeria as reported by (33). The synergistic therapy was very effective and was also dose-dependent. The higher potency attained by the synergistic therapy at the maximum doses administered (200 and 400 mg kg-1 body weight) may

be due to the presence of certain bioactive compounds which were present in the two extracts (34), apart from the secondary metabolites like saponins, flavonoids and steroids were present in both extracts(33).

Toxicology and histo-pathological study of synergistic ethanolic extract of *Alstonia boonei* and *Capsicum frutescens* on the liver enzymes and kidney function can serve as herbal remedy which in most cases is a combination of two or more plants is usually taken for the treatment of malaria or typhoid and other ailments most especially in west Africa. The result obtained from Table 5 and 6 showed increased activities on the liver enzymes and kidney functions on administration of the synergistic extract.

The hematological parameters was not fall below the threshold which could pose danger to the test animals, however, an increase in these hematological parameters following the withdrawal of the plants shows that; administration of the extract had reducing effects on them. A basal level of AST and ALT is found in the plasma which may increase when there is damage caused on the liver and kidney. Increase in the serum level of ALP indicates liver injury or hepatitis (35).which was not observed during this research on test animal. The reference values for AST (0 to 40 U/L) and ALT (0 to 45 IU/L) in human (36) showed that all values obtained for these enzymes from all the plants at both doses and at 7 and 21 days were not significantly higher than normal and it was evidently clear that there was no damage to the liver cell. The increase in the activities of these enzymes after 7 days is indicative of the toxic effects of the extract of the stem bark extract of *A. boonei*. Subsequent decrease in the serum activities of these enzymes after 21 days did not reveal complete recovery (36).

Microscopic examination of the liver and kidney sections after the recovery period shows moderate atrophy of the hepatic cord and accentuation of sinusoids at a lower dose of 1000mg/kg, Centrilobular hepatocellular generation, necrosis and inflammation (2000 and 4000) mg/kg more so, there is tubular epithelial coagulation necrosis and attenuation on the kidney, which was removed in the test animal, evident that the test plant is not toxic. The congestion observed in the liver is evidence that the liver is involved in the biotransformation of xenobiotic (36).

The kidney is an organ for excretion; therefore, it is exposed to both metabolized and un-metabolized toxicant for their removal from the body; the heavy task for the removal of toxicant from the body may cause much damage for the kidney. It was observed that there is no clear demarcation of injury to the kidney of the test animal. This means that high dose of synergistic ethanolic extract of stem bark extract of *Alstonia boonei* and *Capsicum annum* is both not hepatotoxic and nephrotoxic compared to treatment of the negative control groups with water did not show any noticeable effects on the hematological parameters, marker enzymes and histological evaluation (37,38).

However, the potency of the synergistic ethanolic extracts of *Alstonia boonei* and *Capsicum frutescens* at different dose levels were not in doubt as up to 91.7% suppression of malaria parasite and typhoid. These extracts could be utilized for the trial of some newer antimalarial/anti-typhoid drugs in future in view of the constant development of resistance of malaria to currently used drugs. This same extract should be utilized with caution as it is dose sensitive and may cause hematological damage to the liver and kidney (38).

V. CONCLUSION AND RECOMMENDATION

Taking together, the results obtained from this research work shows the efficacy of a synergistic ethanolic extract of *Alstonia boonei* and *Capsicum frutescens* compared with aqueous extract to cure malaria and typhoid in a Swiss Albino Mice. Ethanolic extract of *Alstonia boonei* and *Capsicum frutescens* is suggested to be very effective in the treatment of malaria/typhoid.

This research work suggested a moderate intake of herbal formulation for the treatment of malaria/typhoid because of the possible side effects. The synergistic extract of *Alstonia boonei* and *Capsicum frutescens* are not only toxic, but also recovery from the toxic effects is not within a short-term limit. Although, administration of herbal medicines may be useful in the treatment of diseases, the secondary adverse effects must not be overlooked because in some cases, these side effects are more deleterious than the diseases these phytochemicals are originally used to treat. In conclusion, the safety of the administration of herbs must be considered when using them for therapeutic and prophylactic purposes.

Recommendation

In view of this findings, efforts should be made to further:

- I. Characterize the active components of this plant; and
- II. Elucidate the mechanisms of action of its components on malaria parasite and typhoid.
- III. Experimentally show the lethal dose to be used.

CONSENT

It is not applicable.

ETHICAL APPROVAL

It is not applicable.

ACKNOWLEDGEMENTS

All the technical staffs of the laboratory unit of Both the Department of Microbiology, Faculty of Science, Adekunle Ajasin University, Akungba Akoko, Ondo State, Nigeria, for their support and all the technical assistance rendered during the course of this research work.

COMPETING INTERESTS

Authors have declared that no competing interests exist.

REFERENCES

- [1]. Nkono, R. L. N. Y., Sokeng, S. D., Désiré, D. D. P., Kamtchouing, P. (2014). Antihyperglycemic and Antioxidant Properties of *Alstonia boonei* De Wild. (Apocynaceae) Stem Bark Aqueous Extract in Dexamethasone-Induced Hyperglycemic Rats, *International Journal of Diabetes Research*, 3(3): 27-35
- [2]. Bantie LM(2014). *In vivo* antimalarial activity of the crude root and fruit extracts of *Croton macrostachyus* (Euphorbiaceae) against *Plasmodium berghei* in mice. *Journal of Traditional and Complementary Medicine*.2014;4:1–6. DOI: 10.4103/2225-4110.124323
- [3]. Mensah, A. Y., Donkor, P. O. & Fleischer, T. C. (2011). Anti-Inflammatory And Antioxidant Activities Of The Leaves Of *Wissadula Amplissima* Var *Rostrata*. *African Journal of Traditional, Complementary and Alternative Medicines*, 8.
- [4]. Osuagwu, G. G. E., Onwuegbuchulam, N. P. (2015). The Phytochemical Screening and Antimicrobial Activity of the Leaves of *Monodora myristica*, (Gaertn) Dunal, *Acanthus montanus* (Ness) T. Anders and *Alstonia bonnie* De Wild, *International Journal of Pharmacy and Pharmaceutical Research*, 2(4), 85 – 102.
- [5]. Oladunmoye MK, Kehinde FY(2011).Ethnobotanical survey of medical plants used in treating viral infections among Yoruba tribe of South Western Nigeria.African. *Journal of Microbiology Research*. 2011;5(19):2991–3004.
- [6]. Adebayo, J.O., and A.U., Krettli. (2011). Potential antimalarials from Nigerian plants: A review. *Journal Ethnopharmacology.*, 133: 289-302.
- [7]. Amole, O.O., Ilori, O.O. (2010). Antimicrobial Activity of the Aqueous and ethanolic Extracts of the Stem Bark of *Alstonia boonei*, *International Journal of Phytopharmacology*, 1(2), 119-123.
- [8]. Akinloye, O. A., Oshilaja, R. T., Okelanfa, O. A., Akinloye, D. I., Idowu, O. (2013). Hypoglycemic Activity of *Alstonia boonei* Stem Bark Extract in Mice, *Agriculture and Biology Journal of North America*, 4(1), 1-5.
- [9]. Winter, C. A., Risley, E. A. & Nuss, G. W.(1962). Carrageenin-induced edema in hind paw of the rat as an assay for antiinflammatory drugs. *Proc Soc Exp Biol Med*, 111, 544-7.
- [10]. Fetse, J. P., Kyekyeku, J. O., Dueve, E., Mensah, K. B. (2014). Wound Healing Activity of Total Alkaloidal Extract of the Root Bark of *Alstonia boonei* (Apocynaceae), *British Journal of Pharmaceutical Research*, 4(23), 2642-265
- [11]. Akinpelu DA, Abioye EO, Aiyegoro OA, Akinpelu OF, Okoh AI(2015). Evaluation of antibacterial and antifungal properties of *Alchornea laxiflora* (Benth) Pax and Hoffman. Evidence-Based Complementary and Alternative Medicine. 2015;2015:1-6. Article ID 684839.
- [12]. Hadi, V Bremner, J. B. (2001) "Initial studies on alkaloids from Lombok medicinal plants," *Molecules*, vol. 6, no. 2, pp. 117– 129.
- [13]. Kabita N, Mendes SV, Sheeba E(2015). Antibacterial activity of different extracts of medicinal plant *Swertia chirata*. *Int. J. Curr. Microbiol. Appl. Sci.* 2015;4(7):889-97.
- [14]. Osuntokun, O. T., Oluwafoise B. O. (2015). Phytochemical Screening of Ten Nigerian Medicinal Plants, *International Journal of Multidisciplinary Research and Development*, 2(4), 390-396.
- [15]. Alaribe *et al.*, (2011). Alaribe, C.S.A., H.A.B. Corker, F.O., Shode, G., Ayeola and Adesegun, S.A. (2011).Antiplasmodial and phytochemical investigation of leaf extract of *Anthocleista vogelii* (Planch). *J. Nat. Prod.*, 5: 60-67.
- [16]. Akkawi M, Abbasi I, Jaber S, Aburemeleh Q, Naseredin A, Pierre L(2014). Investigation of traditional Palestinian medicinal plant *Inula viscosa* as potential antimalarial agent. *British Journal of Pharmacology and Toxicology*. 2014;5:156-162.
- [17]. Majekodunmi, S. O. (S. O.)2007 "Formulation of the extract of the stem bark of *Alstonia boonei* as tablet dosage form," *Tropical Journal of Pharmaceutical Research*, vol. 7, no. 2, pp. 987–994, S. O.
- [18]. Osuntokun OT, Olajubu FA(2015). Antibacteria and phytochemical properties of some Nigerian medicinal plants on *Salmonella typhi* and *Salmonella paratyphi* isolated from human stool in Owo Local Government, Ondo State, Nigeria. *Journal of Scientific Research and Reports*. 2015; 4(5):441-449.
- [19]. David, A.F., Philip, J. R., Simon, L.C., Reto, B., Solomon, N., (2004). *Nature Reviews*, 3:509-520.
- [20]. Idu M, Ndukwu BC(2006). Studies of plant used in Ethnomedicine in Ethiope Council Area of Delta State, Nigeria. *Res J Bot.* 2006; 1(1):30-43.
- [21]. Jambou R, Legrand E, Niang M(2005). Resistance of *Plasmodium falciparum* field isolates to in-vitro artemether and point mutations of the SERCA-type PfATPase6. *Lancet* 2005;366:1960-1963
- [22]. Portet C, Taberna PL, Simon P, Flahaut E(2005). Influence of carbon nanotubes addition on carbon-carbon supercapacitor performances in organic electrolyte. *J Power Sources* 2005;139(1–2):371–8
- [23]. Wichmann, O(2004). Risk factors and clinical features associated with severe dengue infection in adults and children during the 2001 epidemic in Chonburi, Thailand. *Trop. Med. Int. Health* 9, 1022–1029 (2004)
- [24]. Newman, D.J., (2008). Natural products as leads to potential drugs: an old process or the new hope for drug discovery? *Journal Medical Chemistry*.51: 2589–2599.
- [25]. Irene, I.I. and U.A. Iheanacho, (2007). Acute effect of administration of ethanol extracts of *Ficus exasperata* vahl on kidney function in albino rats. *J. Med. Plant Res.*, 1: 27-29.
- [26]. Saganuwan SA, Gulumbe ML(2005a) In vitro antimicrobial activities testing of *Abrus precatorius* cold water leaf extract on *Salmonella typhimurium*, *Escherichia coli* and *klebsiella pneumoniae*. *Science Technology Research*. 2005a; 4(3):70–73.
- [27]. Alli, L. A., Adesokan, A. A., Salawu, O. A., Akanji, M. A., Tijani A. Y. (2011). Antiplasmodial activity of aqueous root extract of *Acacia nilotica*. *Africa Journal. Biochemistry Research* 5(7); Pp. 214-219 ISSN 1996-0778
- [28]. Ayoola, G.A., Coker, H.A.B., Adesegun, S.A., Adepoju-Bello, A.A., Obaweya, K., Ezennia, E.C., Atangbayila, T.O., (2008). Phytochemical screening and antioxidant activities of some selected medicinal plants used for malaria therapy in southwestern Nigeria. *Tropical Journal Pharmaceutical Resource.*,7(3): 1019-1024
- [29]. Etkin, N.L., (2003). The coevolution of people, plants and parasites: Biology and Fabricant, D.S., Farnsworth, N.R., (2001). "The value of plants used in traditional medicine for drug discovery". *Environmental Health Perspective*. 109 Suppl 1: 69–75. doi:10.12 89/ehp.01109s 169. PMC 1240543 PMID 11250806
- [30]. **Oludare Temitope Osuntokun**, Histo-Pathological Evaluations of the Effect of Stem Bark Extract of *Spondias mombin* (Linn) on Organs of Albino Rats, (2018). *International Journal of Advances in Medical Sciences*, Feb. 2018 | Vol.3 | Issue 2 |09-18, ISSN: 24566659 Pp 10– 18. **India**.
- [31]. **Osuntokun OT** and **Oluduro AO**(2018) In-Vivo Toxicity Assessment of Stem Bark Extracts of *Spondias mombin* (Linn) on Male and Female Albino Rats., *Open Access Journal of Pharmaceutical Research* ISSN: 2574-7797 ,Volume 2(1): 000152.
- [32]. Bello, I. S., Oduola, T., Adeosun, O.G., Omisore, N. O. A., Raheem, G. O., Ademosun, A.A. (2009). "Evaluation of antimalarial activity of various Fractions of *Morinda lucida* leaf extract and *Alstonia boonei* stem bark," *Global Journal of Pharmacology*, vol. 3, pp. 163–165.
- [33]. Igoli, J.O., O.G. Ogaji, T.A. Tor-Anyiin and N.P. Igoli, (2005). Traditional medicine practice amongst the Igede people of Nigeria. Part II. Africa. *Journal Traditional Complementary Alternative Medicine.*, 2: 134-152.
- [34]. Kingsley, O.A., A. Oseni Lateef, Q. Olga, A. Stephen and T. Mavis, (2012). A comparative evaluation of in vivo antiplasmodial activity of aqueous leaf extracts of *Carica papaya*, *Azadirachta indica*, *Magnifera indica* and the combination thereof using *Plasmodium infected balb/c* mice. *International Journal Applied Biology Pharmaceutical Technology.*, 3: 372-378.
- [35]. Gowder SJT, McMartin KE (2010) Development of a primary culture system of rat kidney proximal tubule cells for transport studies. *J Epithelial BiolPharmacol* 3:15-19

- [36]. Iyiola, O. A., Nneji, L. M., Mustapha, M. K., Nzeh, C. G., Oladipo, S. O., Nneji, I. C., Okeyoyin, A. O., Nwani, C. D., Ugwumba, O. A., Ugwumba, A. A. A., Faturoti, E. O., Wang, Y., Chen, J., Wang, W. Z. and Adeola, A. C. (2018). DNA barcoding of economically important freshwater fish species from north central Nigeria uncovers cryptic diversity. *Ecology and Evolution* 8:6932-6951
- [37]. Martinez, M., Lazaro, R., Olmo L. and Benito, P.(2008),Anti-infectious activity in the anthemi deae tribe. In: Atta-ur- (Ed.) *Studies in Natural Products Chemistry*, Vol. 35. Elsevier. pp 445-516
- [38]. Martin-Moreno, Jose M., Gorgojo, Lydia., Banegas, Jose R., Rodriguez-Artalejo,, Fernando.Fer nandez-Rodriguez., Juan C., Maisonneuve, Patrick., Boyle Peter,*et al.* (1994)."Dietary fat, olive oil intake and breast cancer risk".*International Journal of Cancer*.58 (6):774–780. doi:10.1002 /ijc.2910580604. PMID 7927867.
- [39]. Lorke (1983),A new approach to practical acute toxicity testing. *Archive` of Toxicology* 54: 275–287.