# Healing of a Chronic Diabetic Foot Ulcer During Siddha External Therapy with Mathan Thylam: A Case Report.

**M. Latha Rani[1], U. Nevis Anto[2]**

**[1]Professor, Sri Sairam Siddha Medical College & Research Centre, West Tambaram, Chennai – 600044, Tamil Nadu, India**

**[2]Deputy Medical Superintendent, Sri Sairam Siddha Medical College & Research Centre, West Tambaram, Chennai – 600044, Tamil Nadu, India**

**DOI: https://doi.org/10.47772/IJRISS.2026.101000140**

**Received: 10 October 2026; Accepted: 15 October 2026; Published: 30 October 2026**

## ABSTRACT

### Background

*Madhu Mega Viranam* (Diabetic foot ulcers) are among the clinically important complications of diabetes mellitus and may result in prolonged wound healing, recurrent infection, functional impairment, and, in severe cases, limb amputation. Impaired sensation, vascular insufficiency, altered immune responses, and disturbances in tissue repair contribute to delayed healing. Siddha medicine employs various external therapeutic approaches for chronic and non-healing ulcers, including medicated oils administered as *Veli Maruthuvam*.

### Objective

To document the clinical course of a *Madhu Mega Viranam* (chronic diabetic foot ulcer) managed with external application of the Siddha formulation *Mathan Thylam* as part of external wound care.

### Case Presentation

A 52-year-old female with a 13-year history of type 2 diabetes mellitus presented with a chronic non-healing ulcer on the plantar aspect of the right foot for 2 months. The ulcer had developed following minor trauma approximately two months before presentation and had shown inadequate healing despite previous routine wound care and antibiotic treatment. At baseline, the ulcer measured 3.2 ×2 cm and showed slough, mild serous discharge, irregular margins, and callous formation. Sensation over the affected area was reduced.

### Intervention

The ulcer was cleansed with sterile normal saline, Debridement f callus, cleaned with *thiriphala decocotion*, and *Mathan Thylam* was applied externally once daily, followed by sterile dressing. The intervention was continued for 23 days. Supportive measures included advice regarding glycaemic control, foot hygiene, and avoidance of pressure over the affected site.

### Outcome

Progressive reduction in ulcer dimensions was observed during follow-up. The ulcer measured 2.7 × 1.8 cm on day 1.9 x 1.2 cm on day 10, and 0.8 × 0.7 cm on day 14. Healthy granulation tissue developed by day 10, followed by progressive epithelialization. Complete clinical closure was observed on day 23. No clinically significant local adverse effects were documented during the treatment period.

### Conclusion

Complete clinical healing of the *Madhu Mega Viranam* (diabetic foot ulcer) was observed during 23 days of treatment incorporating topical *Mathan Thylam and* Internal Siddha medications, *Seenthil Choornam* and *Avarai*

*Kudineer*, were administered as adjunctive therapies. This case provides preliminary clinical documentation supporting further investigation of this Siddha external formulation in diabetic wound management. However, a causal therapeutic effect cannot be established from a single uncontrolled case, and controlled clinical studies with standardized outcome measures and longer follow-up are required.

**Keywords:** Madhu Mega Viranam, diabetic foot ulcer, Mathan Thylam, wound healing.

# INTRODUCTION

Diabetes mellitus is a chronic metabolic disorder associated with multiple systemic and vascular complications [1]. One of its important clinical manifestations is the *Madhu Mega Viranam* (diabetic foot ulcer), which develops through a combination of neuropathy, mechanical stress, vascular abnormalities, impaired host defence, and defective tissue repair [2]. *Madhu Mega Viranam* (Diabetic foot ulcers) can become chronic and are associated with substantial morbidity and a risk of infection, hospitalization, and lower-limb amputation [3]. Approximately 50% to 60% of ulcers become infected, and about 20% of moderate to severe infection led to lower extremity amputations [4].

Peripheral neuropathy is particularly important because reduced protective sensation may allow minor trauma or repetitive pressure to progress unnoticed [5]. In addition, peripheral arterial disease can compromise tissue perfusion, while metabolic abnormalities associated with prolonged hyperglycaemia can adversely affect inflammatory responses, angiogenesis, collagen formation, and epithelial repair.

Management of *Madhu Mega Viranam* (diabetic foot ulcers) generally requires a multidisciplinary approach. Depending on the clinical condition, appropriate management may include wound cleansing, debridement, infection control, pressure redistribution or off-loading, vascular assessment, glycaemic management, and suitable wound dressings [6]. The choice of treatment should be guided by wound characteristics and the patient's overall clinical status.

Siddha medicine has traditionally employed specialized approaches for chronic wounds and non-healing ulcers. External therapeutic procedures, collectively described under *Pura Maruthuvam*, include the use of medicated oils, pastes, powders, and other topical preparations. Chronic ulcers are described in Siddha literature under different clinical categories according to their duration, characteristics, discharge, tissue involvement, and associated symptoms.

*Mathan Thylam* [7] is a Siddha medicated oil traditionally used as an external preparation for selected ulcerative and inflammatory conditions. The oil is prepared from purified *Thurusu* (Copper sulphate), *Umaththai juice* (Datura metal), *Kuppaimeni* juice (Acalypha indica) and coconut oil. In Siddha therapeutic terminology, properties such as *Pun Aatral* and actions directed towards pain and swelling are considered relevant to the management of chronic wounds.

Internal Siddha medications, *Seenthil Choornam* [8] and *Avarai Kudineer* [9], were administered as adjunctive therapies. *Seenthil Choornam* was given orally twice daily with water after meals, while *Avarai Kudineer* was administered orally at a dose of 60 mL twice daily after meals. Concurrent conventional antibiotic therapy was prescribed for one week. For local wound management, *Mathan Thylam* was applied topically to the ulcer once daily, followed by sterile dressing. This topical treatment was continued for 23 consecutive days, with periodic clinical assessments to monitor wound healing and document changes in ulcer characteristics.

The present case report describes the clinical progression of a chronic diabetic foot ulcer in a patient during treatment incorporating external application of *Mathan Thylam*. The report aims to document the clinical observations and provide a basis for further systematic evaluation of this traditional external therapy.

# CASE PRESENTATION

## 2.1 Patient Information

A 52-year-old female patient presented with a chronic ulcer involving the plantar aspect of the right foot. She

had a documented history of type 2 diabetes mellitus of approximately 13 years' duration and was receiving oral hypoglycaemic agents for glycaemic control. There was no previous history of foot ulceration. Her personal history revealed no habitual betel nut chewing or smoking. She followed a non-vegetarian diet and reported consuming unsweetened tea twice daily. The ulcer had developed following minor trauma approximately two months prior to presentation and had failed to heal satisfactorily despite previous routine wound dressing and antibiotic therapy. In view of the chronicity of the lesion and the inadequate response to previous treatment, the patient sought Siddha medical management.

**Table 1. Complaints and duration of the patient**

| Parameter | Details |
|---|---|
| Age | 52 years |
| Sex | Female |
| Occupation | House wife |
| Relevant medical history | Type 2 diabetes mellitus for 13 years |
| Antidiabetic treatment | Oral hypoglycaemic medication |
| Site of ulcer | Plantar aspect of right foot |
| Approximate duration of ulcer | 2 months |
| Preceding event | Minor trauma |
| Previous management | Routine wound dressing and antibiotic treatment |

## CLINICAL EXAMINATION

At the initial clinical examination, a painless ulcer measuring approximately 3.2 ×2 cm was observed on the plantar aspect of the right foot. The ulcer was characterized by irregular margins, a slough-covered wound bed, and mild serous exudation. Perilesional callus formation was evident, along with diminished sensation in the affected area, suggestive of peripheral sensory impairment. The dorsalis pedis and posterior tibial pulses were palpable on clinical examination, indicating clinically detectable peripheral arterial pulsations. No venous tortuosity, pedal oedema, and cutaneous hyperpigmentation was observed. Based on the available clinical records, there was no documented evidence of severe systemic infection at the time of presentation.

According to Siddha diagnostic principles, *Naadi* examination revealed an abnormal *Vatha-Pitha* pulse pattern characterized by pendulum-like pulsations, which was interpreted within the Siddha diagnostic framework as an indication of humoral imbalance associated with poorly controlled diabetes mellitus. Urine assessment included *Neerkuri* and *Neikuri* examinations, with the latter demonstrating a snake-like pattern of oil dispersion. Routine urinalysis revealed glycosuria (urinary sugar, 3+) and trace albuminuria. Biochemical assessment at the initial presentation showed an HbA1c level of 11.2%, indicating poor glycaemic control. By the 23rd day of follow-up, the HbA1c level had decreased to 8.2%, suggesting an improvement in glycaemic status, although optimal glycaemic control had not yet been achieved.

**Table 2. Present wound characteristics**

| Clinical feature | Baseline observation |
|---|---|
| Site | Plantar aspect of right foot |
| Ulcer dimensions | 3.2 ×2 cm |
| Depth | Moderate |
| Wound floor | Slough present |
| Discharge | Mild serous discharge |
| Margin | Irregular |
| Surrounding skin | Callus formation |
| Sensation | Reduced |

**Grading of the Wound:**

The Wagner-Meggitt classification system is a common way to grade diabetic foot ulcers based on the depth of

the ulcer and the presence of infection or gangrene [10] . The grades are:

Grade 0: Only foot symptoms like pain

Grade 1: Superficial ulcer that involves the skin and subcutaneous tissue

Grade 2: Deep ulcer that involves ligaments, muscles or tendon

Grade 3: Ulcer that involves bone

Grade 4: Forefoot gangrene

Grade 5: Full foot gangrene

According to the Wagner–Meggitt classification, the patient's foot ulcer was classified as Grade 1, indicating a superficial ulcer involving the skin and subcutaneous tissue without involvement of deeper structures. This finding was also confirmed by the X-ray examination.

**Diagnosis**

Based on the clinical history and local examination findings, the lesion was clinically diagnosed as a chronic diabetic foot ulcer, corresponding to *Madhu Mega Viranam* within the Siddha system of medicine. From the Siddha perspective, the chronic and non-healing characteristics of the ulcer were correlated with the traditional description of *Madhumega Viranam*. The modern clinical diagnosis and the Siddha diagnostic correlation were documented separately, acknowledging that the two medical systems employ distinct diagnostic principles and classification frameworks.

**TREATMENT INTERVENTION**

**5.1 Internal and External Medicine**

The Siddha formulation *Mathan Thylam* was selected for topical application in accordance with its traditional therapeutic indications. Internal Siddha medications, *Seenthil Choornam* and *Avarai Kudineer*, were administered as adjunctive therapy. *Seenthil Choornam* was given orally twice daily with water after meals, while *Avarai Kudineer* was administered at a dose of 60 mL twice daily after meals. Concurrent conventional antibiotic therapy was prescribed for one week. For local wound management, *Mathan Thylam* was applied externally to the ulcer once daily for 23 consecutive days, followed by sterile dressing. The treatment course was accompanied by periodic clinical assessment to monitor wound healing and document changes in the ulcer characteristics.

Dietary advice was provided in accordance with standard dietary recommendations for diabetes mellitus, emphasizing a balanced diet with controlled carbohydrate intake, adequate dietary fibre, and appropriate portion sizes. The patient was advised to avoid added sugars, refined carbohydrates, and sugar-sweetened beverages, while incorporating whole grains, vegetables, and other nutrient-rich foods. Regular meal timings and adherence to the prescribed dietary regimen were encouraged to support glycaemic control and overall metabolic health.

Lifestyle modification advice was provided as part of the comprehensive management plan, including yoga, meditation, pranayama (controlled breathing exercises), regular physical activity, and walking, along with adequate and regular sleep. These interventions were recommended to promote stress reduction, improve overall physical and psychological well-being, and support glycaemic control. The patient was encouraged to incorporate these practices into her daily routine, taking into account her clinical condition and the need to avoid excessive weight-bearing on the affected foot during the ulcer-healing period.

**5.2 Method of Application**

The wound-management procedure was performed under appropriate clinical conditions. Initially, the ulcer was

gently cleansed with sterile normal saline, followed by the careful removal of visible slough when clinically indicated. Subsequently, the wound was cleansed with *Thiriphala* decoction, after which *Mathan Thylam* was applied uniformly to the affected area. The ulcer was then covered with a sterile dressing, which was changed according to the clinical requirements and wound condition. The patient also received advice on regular glycaemic control, appropriate foot hygiene, and the avoidance of excessive mechanical pressure on the affected foot. The topical treatment regimen was continued for 23 consecutive days, with periodic clinical assessments to monitor wound progression and healing outcomes.

## OUTCOME ASSESSMENT

The primary clinical outcomes evaluated during the follow-up period included changes in ulcer dimensions (measured with measuring tape), wound-bed characteristics, the quantity of exudate, and the development of healthy granulation tissue. The progression of epithelialization and the achievement of complete clinical wound closure were also assessed. In addition, the occurrence of local adverse effects, including irritation, inflammation, or other treatment-related complications, was monitored. Wound dimensions and relevant clinical characteristics were systematically documented at successive follow-up visits to evaluate the progression of healing throughout the treatment period.

**Table 3. Clinical progression of the diabetic foot ulcer**

| Day | Ulcer size | Wound floor | Discharge | Clinical observation |
|---|---|---|---|---|
| Day 0 | 3.2 ×2 cm | Slough present | Mild serous | Ulcer with callus formation |
| Day 7 | 2.7 × 1.8 cm | Slough reduced | Minimal | Reduction in size and symptoms |
| Day 10 | 1.9 × 1.2 cm | Healthy granulation tissue | Nil | Progressive healing |
| Day 14 | 0.8 × 0.7 cm | Epithelialization | Nil | Marked wound closure |
| Day 23 | Completely healed | Scar tissue/healed surface | Nil | Complete clinical closure |

## CLINICAL COURSE

During the first week of treatment, a gradual reduction in wound dimensions and discharge was observed. By day 7, the ulcer had decreased from 3.2 ×2 cm to approximately 2.7 × 1.8 cm.

By day 10 assessment, the wound measured approximately 1.9 × 1.2 cm. The amount of slough had decreased, and healthy granulation tissue was visible over the wound bed. No discharge was noted at this stage.

By day 14, the ulcer had further reduced to approximately 0.8 × 0.7 cm, with evidence of progressive epithelialization.

At the day-23 assessment, complete clinical closure of the ulcer was observed. The wound surface appeared healed, with residual scar tissue. No discharge was present.

No clinically significant adverse reaction attributable to the topical treatment was documented during the treatment period.

## PHOTOGRAPHIC DOCUMENTATION

Clinical photographs were obtained at selected stages of treatment following appropriate consent from the patient.

**Figure 1.** Chronic diabetic foot ulcer on the plantar aspect of the right foot before initiation of Siddha treatment (Day 0).

**Figure 2.** Diabetic foot ulcer showing healthy granulation tissue after removing the callus. (Day 1).

**Figure 3.** Granulation tissue formed and wound size reduced.(Day 10)

**Figure. 4.** Wound size reduced, lesion is on healing side. (Day 14)

**Figure 5.** Complete Clinical Healing of the ulcer following 23 days of treatment (Day 23).

**Fig. 1**



**Fig.2**



**Fig. 3**



**Fig. 4**



**Fig 5.**



**Fig. 6 Progressive Reduction in Wound Area During Siddha-Based Management of a Diabetic Foot Ulcer.**

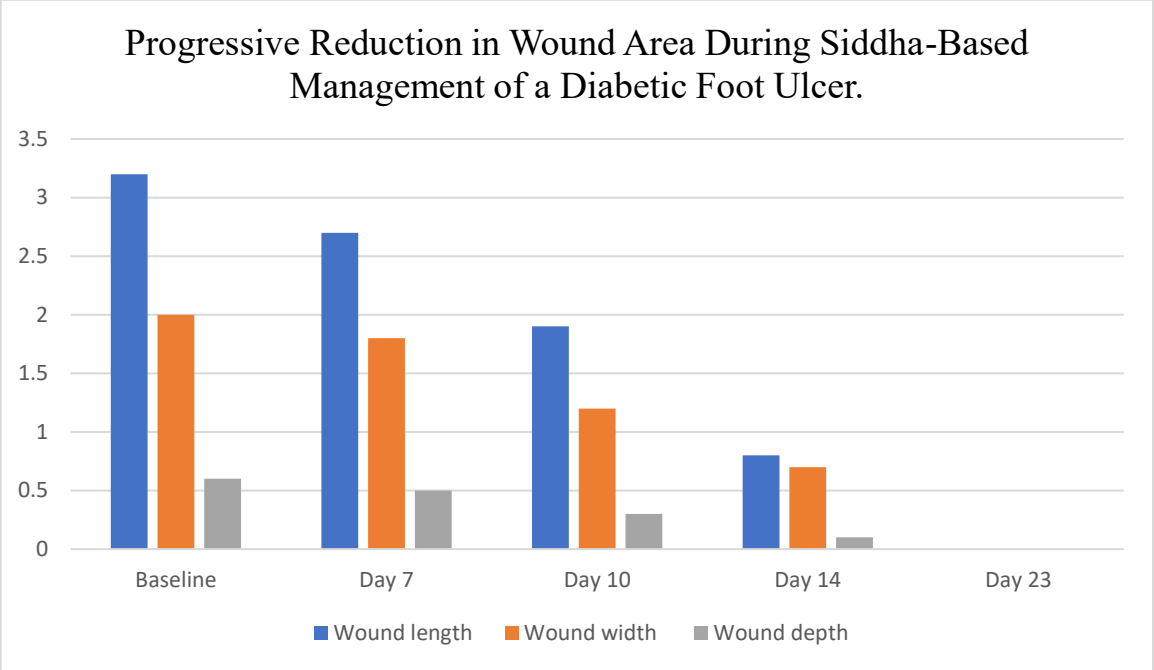


**Fig. 7. Blood Sugar and HbA1c Analysis**

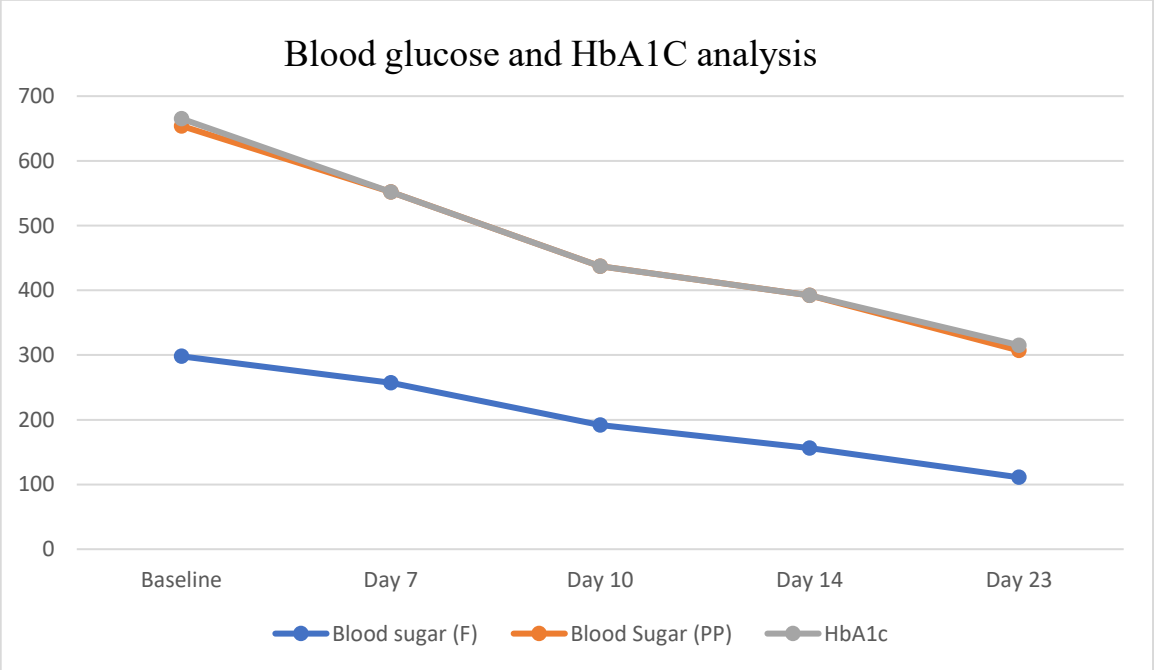


## DISCUSSION

The surgical complications of *Madhu Mega Viranam* (Didbetic Foot Ulcer) was increased due to lack of education, change in life style, and negligence [11]. *Madhu Mega Viranam* (Diabetic foot ulcers) develop through a complex interaction of neuropathy, mechanical stress, vascular insufficiency, inflammation, infection, and impaired tissue repair [12]. Chronic hyperglycaemia can adversely affect several stages of wound healing, including inflammatory regulation, angiogenesis, extracellular matrix formation, and epithelialization [13].

*Mathan thylam* formulation has been reported to possess antimicrobial, anti-inflammatory, antioxidant, and wound-healing properties. Preclinical findings indicate that topical application of *Mathan Thailam* may promote wound repair by enhancing collagen deposition, increasing tensile strength, and facilitating re-epithelialization.

These effects may be associated with the modulation of inflammatory mediators, including TNF-α and IL-10, together with improved antioxidant defences and stimulation of angiogenesis [14].

The postoperative wound in Kangayam cattle was managed with external application of *Mathan Thailam*. The owner was instructed to clean the wound regularly and apply the preparation topically three times daily. During the treatment period, marked improvement in wound closure was observed, suggesting a potential role for *Mathan Thailam* in promoting wound healing in this case. Further controlled clinical studies are required to establish its efficacy and safety [15].

At the end of the 23 days treatment period, the diabetic foot ulcer demonstrated progressive clinical improvement, with its grade decreasing from Grade 1 to Grade 0, indicating complete wound closure. These findings suggest that topical application of *Mathan Thailam* may have a potential role in the management of chronic diabetic foot ulcers [16].

Several medicinal plants have been investigated for their potential antidiabetic properties through the inhibition of carbohydrate-digesting enzymes. Cassia auriculata (whole plant), known as *Avirai*, contains tannins, flavonoids, saponins, terpenoids, and alpha-tocopherol, and has demonstrated inhibitory activity against α-amylase and α-glucosidase [17]. Cassia fistula (bark and leaves), known as *Kondrai*, contains flavonoids, proanthocyanidins, lupeol, saponins, tannins, and triterpenoids, with reported α-amylase inhibitory activity [18]. The seeds of Eugenia jambolana, commonly called *Naaval*, contain flavonoids, myricetin, ellagic acid, tannins, jambosine, and jamboline, and have been associated with α-glucosidase inhibitory activity [19]. Salacia reticulata (whole plant), known as *Kadalazhinjil*, contains salacinol, kotalanol, salaretin, and quercetin, which have been investigated for α-glucosidase inhibition [20]. The rhizome of Cyperus rotundus, known as *Korai Kizhangu*, contains flavonoids, tannins, saponins, cyperene, norcyperone, and β-sitosterol, and has shown inhibitory activity against both α-amylase and α-glucosidase [21] . Similarly, the rhizome of Costus speciosus, known as *Koshtam*, contains eremanthin, saponins, triterpenes, and β-sitosterol, and has been studied for its in vitro effects on α-glucosidase activity [22].The bark of Terminalia arjuna, known as *Marutham*, contains flavonoids, tannins, triterpenoid saponins, arjungenin, luteolin, and arjunic acid, and has demonstrated inhibitory activity against both α-amylase and α-glucosidase, suggesting its potential as a therapeutic agent for the management of type 2 diabetes mellitus. However, further clinical studies are required to establish its efficacy and safety [23].

*Seenthil Chooranam* has been reported to possess diverse pharmacological properties, including antidiabetic, antimicrobial, antioxidant, anti-inflammatory, antiasthmatic, antitumour, immunomodulatory, and wound-healing activities. Its therapeutic potential may be attributed, in part, to bioactive constituents such as alkaloids, flavonoids, terpenoids, and bioactive peptides present in its ingredients. In traditional Siddha practice, this formulation has been indicated for various conditions, including sinusitis, diabetes mellitus, tuberculosis, cough, bronchial asthma, scrotal swelling, alopecia areata, and hair loss [24].

In the present case, the patient was an individual with a long history of type 2 diabetes mellitus and reduced sensation in the affected foot. The ulcer had developed following minor trauma and had persisted for approximately two months despite previous wound care. These characteristics are clinically relevant because sensory impairment may permit repeated unnoticed trauma and contribute to delayed wound healing.

During the 23-day treatment period incorporating topical *Mathan Thylam*, the wound demonstrated a consistent pattern of improvement. The ulcer dimensions decreased progressively, slough diminished, healthy granulation tissue developed, discharge disappeared, and epithelialization proceeded until significant wound-healing potential was observed.

From the Siddha perspective, the management of chronic ulcers includes consideration of the wound's characteristics and the use of external preparations appropriate to the clinical presentation. *Mathan Thylam* is traditionally used as a medicated oil in selected ulcerative conditions. Its oleaginous vehicle may provide a protective topical environment, while the constituents of the formulation may potentially contribute to local wound responses. However, the precise pharmacological mechanisms responsible for the observed clinical changes cannot be determined from this case alone.

The observed improvement should also be interpreted in the context of comprehensive wound care. Wound cleansing, removal of slough when required, sterile dressing, attention to glycaemic control, foot hygiene, and pressure avoidance may all contribute to wound healing. Therefore, the present case does not permit attribution of the entire healing response specifically to *Mathan Thylam*.

The progression from a slough-containing wound to a healthy granulating wound followed by epithelialization represents a clinically favourable sequence of wound repair. Nevertheless, objective wound-healing measures such as percentage area reduction, wound-bed scoring, glycaemic indices, vascular assessment, neuropathy grading, and standardized pain scores would provide stronger evidence in future studies.

An additional limitation is that the case does not provide sufficient information to determine the degree of peripheral arterial disease, if any, or to establish microbiological status. Such assessments are particularly relevant in *Madhu Mega Viranam* (diabetic foot ulcers). Future case series and clinical trials should therefore incorporate standardized assessment of vascular status, neuropathy, infection, glycaemic control, wound dimensions, and recurrence.

The present case is best considered hypothesis-generating. It provides clinical documentation of complete wound closure during treatment incorporating a traditional Siddha external formulation but does not establish comparative efficacy or a specific mechanism of action.

## FOLLOW-UP

The patient should ideally be followed for an extended period after complete wound closure to document wound recurrence, development of new ulcers, and long-term skin integrity.

For future reports, a follow-up period of at least 3–6 months would provide more meaningful information regarding sustained healing and recurrence.

## PATIENT PERSPECTIVE

The patient reported satisfactory improvement in the wound during the treatment period. Progressive reduction in the ulcer and eventual complete closure was observed by the patient and treating clinician.

## CONCLUSION

This case report documents the complete clinical healing of a chronic diabetic foot ulcer over 23 days during an integrative treatment regimen incorporating topical *Mathan Thylam*, internal Siddha medications, conventional antibiotic therapy, wound cleansing, sterile dressing, dietary modification, and lifestyle advice. Progressive reduction in wound dimensions, resolution of exudation, development of healthy granulation tissue, and subsequent epithelialization culminated in complete clinical wound closure with residual scar tissue. A concurrent reduction in HbA1c from 11.2% to 8.2% was also recorded, although glycaemic control remained suboptimal. As multiple therapeutic interventions were administered concurrently, the individual contribution of *Mathan Thylam* to wound healing cannot be established from this single case. Nevertheless, the clinical observations provide a rationale for further systematic investigation of this traditional Siddha formulation. Well-designed prospective clinical studies with standardized formulations, appropriate control groups, objective wound-healing assessments, comprehensive safety evaluation, and long-term follow-up are warranted to establish its efficacy and safety in the management of diabetic foot ulcers.

## ETHICAL CONSIDERATIONS

The patient was managed according to the principles of responsible clinical care. Patient confidentiality was maintained throughout the preparation of the case report.

Where required by the institution or target journal, appropriate institutional ethical approval or exemption should be documented.

**Informed Consent**

Written informed consent was obtained from the patient for treatment and for publication of anonymized clinical information and clinical photographs.

**Conflict of Interest**

The authors declare that there is no conflict of interest.

**Funding**

No external funding was received for the preparation or management of this case.

**Author Contributions**

The treating clinician contributed to patient assessment, treatment, follow-up, documentation of clinical findings, interpretation of the case, and preparation of the manuscript. All authors reviewed and approved the final manuscript.

**Data Availability**

The clinical information supporting the observations described in this case report is presented within the manuscript. Identifying patient information has been excluded to preserve confidentiality.

## REFERENCES

1. U. A. . O. A. S. A. and R. A. M. , Handbook of Clinical Neurology, vol. 126, 2014, pp. 211-222.
2. R. G. Frykberg, "Diabetic Foot Ulcers:Pathogenesis and Management," American family Physician, vol. 66, no. Number 9, pp. 1655-1661, 1 November 2002.
3. W. J. J. and k. G. H. , "Diabetic foot ulcers," The Lancet, vol. 361, no. 9368, p. Diabetic foot ulcers, 3 May 2003.
4. D. G. A. e. al., "Diabetic Foot Ulcers- A Review," JAMA, vol. 330, no. 1, pp. 62-75, 03 July 2023.
5. K. A. &. J. Doupis, "Management of Diabetic Foot Ulcers," Springer Nature Link, vol. 3, no. article no.4, 20 April 2012.
6. N. M. Estelle Everett, Annals of the NewYork Academy of Sciences, vol. 1411, no. 1, pp. 153-165, 29 January 2018.
7. K.S.Uththamarayan, Siddhar Aruvai Maruthuvam, Sivakasi, Tamil Nadu: The Nadar pressLtd., 2013, pp. 66-67.
8. K. K. Mudaliar, Siddha Vaithya Thirattu, Chennai, Tamil Nadu, 1984, Fifth edition, pp. 262-263.
9. M. Mudaliar, Gunapadam Mooligai Vaguppu, Chennai: Arasu maiya Achagam, 1988, fourth edition, p. 65.
10. C. Jakucs, "Diabetic Foot Ulcer Classifications: The Wagner Scale and the UT System," Wound care, June 6, 2023.
11. M. Manohar.R, "To study the surgical complications of Diabetes and their management in the rural population," International Journal of Science and Research, vol. 3, no. 12, pp. 1979-1980, December 2014.
12. B. A. B. S. Armstrong DG, "Diabetic foot ulcers and their recurrence," New England Journal of Medicine , vol. 376, no. 24, p. 2367–2375., 2017.
13. B. J. Frykberg RG, "Challenges in the treatment of chronic wounds.," Advances in Wound Care, vol. 4, no. 9, p. 560–582, 2015.
14. N. T. K. M. P. Bhavana Kumari, "Wound Healing and Pharmacological Properties of the Siddha Formulation Mathan Thailam: A Narrative Review," Integrated Health Research Journal, vol. 3 , no. No. (1-Supp) (2026): SPECIAL ISSUE: Traditional and Herbal Medicine: Bridging Ancient Wisdom and Modern Health Research, 01 June 2026.

15. M. Selvaraju, M. Periyannan and Varudharajan, “Rejuvenating Effect of Mathan Thailam for a Wound Dehiscence following Caesarean Operation in a Kangayam Cow Affected with Uterine Torsion.,” Indian Journal of Animal Research, vol. 56, no. 4, p. 502, 2022.
16. G. Kishore, K. P. Kannan and G. Vinitha, “Effective Management of Chronic Diabetic Foot Ulcer Through Siddha Treatment -- A Case Series.,” Journal of Chemical Health Risks, vol. 16, no. 4, p. 2227, 2026.
17. N. T. Shravan Kumar, “.Invitro anti-diabetic activity of seed extracts of Cassiaauriculata and Cassia angustifolia,” Eur J Exp Biol., vol. 5, no. 5, pp. 12-17, 2015.
18. A. A. M., “Anti hyperglycemic and analgesic activities of ethanolic ext. of Cassia fistula(L) stem bark.,” Int J Pharm Sci Res., vol. 3, no. 2, pp. 416-423.
19. F. M. H. &. W. G. W. N. M. Y. &. X. Y. H. X. L. L. Liu, “Phenolics from Eugenia jambolana seeds with advanced glycation endproduct formation and alpha-glucosidase inhibitory activities,” Food Funct., vol. 9, no. 8, pp. 4246-4254, 2018.
20. S. A. S. K. R. G. Ramakrishna D, “SalaciaSps – A Potent source of herbal drug for Anti-diabeticand Antiobesity ailments : A detailed reatise.,” Int J Pharm Pharm Res, vol. 7, no. 2, pp. 374-382, 2015.
21. L. H. N. T. Nguyen MC, “Inhibitors of alphaglucosidase and alphaamylase from cyperusrotundus,” .Pharm Biol. , vol. 52, no. 1, pp. 74-77, 2014.
22. O. A. A. M. E. HaythamAli A, “Molecular mechanisms of anti hyperglycemic effects of Costusspeciosus extract in Streptozotocin induced diabetic rats.,” Saudi Med J. , vol. 35, no. 12, pp. 1501-1506, 2014.
23. P. S. G. J. C. R. J. G. K. Rajalakshmi, “Effect of Avarai Kudineer on α- Amylase and αGlucosidase Inhibition: A Preclinical Antidiabetic Study,” Journal of Pharmaceutical Research International , vol. 33, no. 47A, pp. 818-825, 2021;.
24. J. J. Sheeba, K. Sivaranjani and L. Santhoshkumar, “A review on therapeutic effect of Siddha classical formulation Seenthil Chooranam.,” Journal of Drug Delivery & Therapeutics, vol. 15, no. n.3, p. 151, 2025.