

Harnessing Artificial Intelligence for Enhanced Diagnostic Accuracy in Dentistry

Saiprabha Sivakumar Inika^a, Vikas Rao Naidu^{b*}

^aDental Surgeon, Al Salama Polyclinic, Sultanate of Oman

^bAssistant Professor, Middle East College, Sultanate of Oman

DOI : <https://doi.org/10.51244/IJRSI.2024.1114SDAICO17>

Received: 04 July 2024; Accepted: 25 July 2024; Published: 04 November 2024

ABSTRACT

Artificial intelligence (AI) is the branch of computer science dedicated to building systems to perform tasks that normally require human intelligence. AI tries to solve problems and learn similar to humans. The field of AI has experienced phenomenal development and growth over the past two decades; with the latest developments in digitized data collection, machine learning, and computing infrastructure, AI applications are expanding rapidly, especially in areas that are thought to be reserved for experts in their fields. Artificial intelligence has started to take place rapidly in dental clinical applications. The use of artificial intelligence in dentistry has enormous potential to improve patient care and drive major advances in healthcare. AI in dentistry is being researched for various purposes, such as identifying anatomical and pathological structures, diagnosing diseases and predicting treatment results, and selecting materials to be used. Advances in AI offer healthcare benefits, such as reducing postoperative complications, improving quality of life, and reducing the number of unnecessary procedures. It can also play a great helping role for dentists in increasing the accuracy of diagnosis. This study aims to explain the current applications and future predictions of artificial intelligence in dentistry, which is one of the most current topics of recent times.

Keywords: Artificial Intelligence, Diagnostic Accuracy, Dentistry, Machine Learning, Dental Imaging.

INTRODUCTION

The term artificial intelligence (AI), defined as “the ability of a device to perform functions normally associated with human intelligence, such as reasoning, learning, and self-development,” continues to occupy a large place in our lives at an ever-increasing pace. The first question was asked by Alan Turing in 1950 as “Can machine think?” and then the term was first used by John McCarthy as “Artificial Intelligence”.

The complexity of neural networks in a functional human brain has always been a topic of interest to many researchers in different fields. With the development of science over time, many advanced technology products have emerged that imitate the functions of the human brain, but it is still not possible to fully simulate the human brain today. Despite the many difficulties experienced, “artificial intelligence” (AI) has gained great importance in all areas of life with its irrepressible progress. Artificial intelligence (AI) studies, which continue to develop at an ever-increasing pace, are candidates to change and advance dentistry, as in many disciplines. Some of the situations that accelerate the developments such as the increase in computer power, the ease of access to universal information, and the availability of big data ready to be processed with AI applications in the field of health; it is the use of terms such as “digital transformations,” “digitalized workflows,” “technical developments” both in social life and in dentistry. AI studies basically aim to imitate the cognitive processes of human intelligence by using machines and software-type algorithms to manage possible problems and complex tasks solved by human mind and skill.

AI is a science under Computer Science or Computer Engineering. The sub-branches of AI are symbolic or machine learning. Machine learning is an algorithm that refers to the study of computer models that improve their performance by learning from experience without using explicit instructions, so it needs sample data to make predictions or decisions [10]. Preparing datasets for AI requires large amounts of data to be processed to improve accuracy. The experts must invest time and effort in making data suitable for effective learning. Deep learning and statistical learning are sub-branches of machine learning.

Machine learning (ML) is a branch of artificial intelligence in which systems learn to perform intelligent tasks without prior knowledge or hand-made rules, identifying patterns in samples from a large dataset without human assistance. This system can optimize its adjustable functions by defining a goal and achieving it. In this process, known as training, a machine learning algorithm is exposed to random samples. It then defines patterns that it can apply to new images as it gains experience by gradually adjusting the “tunables” toward the correct answer. Machine learning is basically like an adult showing a child several photos of cats, and eventually, the child learns the patterns of recognizing a cat in new images.

Deep learning (DL) is a sub-branch of ML. In this system, it is aimed to learn not only a model, but also a hierarchy of malleable models that are built on top of each other. The combination of dies creates a “deep” system that is much stronger than a flat, “shallow” system. For example, a child does not identify a cat in a single and indivisible pattern-matching step. The child sees the edges of the object first and defines a sketch with simple shapes such as eyes, nose, and ears, making a specific grouping. Among these components, larger groups emerge, such as the head, trunk, and legs. A particular group of these large groups also defines the whole cat.

Developments in computer technologies have increased the studies on AI and the interest in the subject. In this way, scientific studies have been facilitated, and neuropsychological, psychological, and similar behaviors can be perceived in three dimensions, especially for a better understanding of the brain. Thanks to the recording of sudden metabolic activities in the brain tissue with magnetic resonance imaging, some predetermined mental functions can be investigated, and the results obtained make great contributions to a better understanding of the working principle of the brain. In the future, it will be possible to contribute more to the development of AI techniques with the results obtained from the studies carried out to illuminate the working principle of the brain.

Since dentistry is one of the areas where technology is most widely used, it is a very open area for developments in technology and the adaptation of AI applications. In recent years, AI applications have been widely used in dentistry, ranging from the diagnosis of caries, and the detection of various pathologies, to robotic surgery and dental implant construction.

The compatibility of dental radiology with image processing methods has made AI studies even more prominent in the field of radiology. There are many studies in AI that is applied on 2D and 3D (2D/3D) radiographic images. Detection of gingival diseases and evaluation of risk groups; automatic marking of anatomical structures and performing cephalometric analysis; diagnosis of certain diseases such as osteoporosis, which can be detected in X-rays of the jaw, etc., applications are just some of the studies on this subject.

With the rapid developments in the field, AI studies, which have started to radically change the sectors, will inevitably transform dentistry. The purpose of this section is to review the current and potential uses of AI applications in dentistry, to discuss the opportunities it will offer to improve oral and dental health of the community, and to examine its possible contributions to the economy and education.

Artificial intelligence applications in dentistry

As described in the previous section, AI is currently used in dentistry and in is explained in detail.

Dentomaxillofacial radiology

Dentistry examines the conditions and pathologies seen in the mouth, teeth, and jaws by establishing a

relationship between clinical, systemic, and radiological findings. The patient's anamnesis and complaint history, digital radiography images, and, when necessary, intraoral/extraoral photographs are recorded. Oral diseases such as dental caries, gingival diseases, inflammatory conditions, cysts, and tumors are commonly evaluated with these instruments. The schematization of the detection of dental caries on radiographs by AI algorithms is shown in Figure 1.

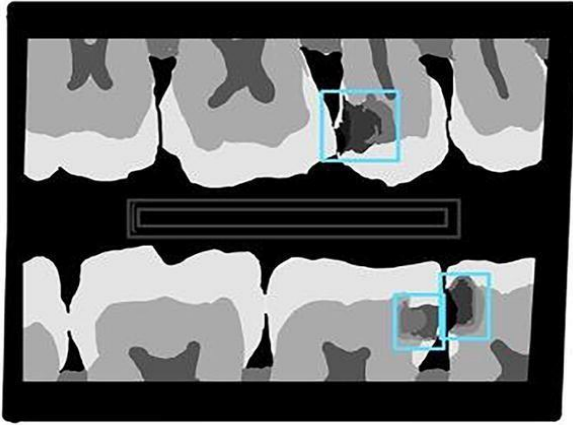


Figure 1. Illustration of dental caries marked (blue boxes) on Bitewing radiographs.

Digital radiographs, radiographic images produced by X-ray irradiation are digitally encoded and easily translated into computational language. Thanks to this digitalization in radiographs, the development of artificial intelligence in the field of radiology has accelerated and increased. Dental radiography, that is, intraoral radiographs, panoramic, cephalometric and advanced imaging technique, and cone beam computed tomography (CBCT), are collected for diagnosis, treatment planning, and treatment evaluation purposes during routine dental practice. As such, these large datasets offer a rich resource for scientific and medical research, especially for use in AI development work. In radiology practice, findings are visually evaluated and interpreted by radiologists according to the characteristics of the images; however, this assessment can often be subjective and time consuming. In contrast, AI methods provide automatic recognition and quantitative analysis of complex patterns in imaging data. Therefore, AI can be used as an effective tool to help clinicians make more objective and reproducible assessments of radiological images. While radiographs are interpreted by dentists, first of all, certain radiological features of normal tissues and pathologies are recognized and distinguished from each other, and then, preliminary diagnoses and differential diagnoses are created by overlapping the obtained radiographic information with clinical findings.

The first recognition and discrimination process is basically a pattern recognition function. Some radiographic analyses can now be done automatically, thanks to the fact that machine learning techniques allow computers to recognize patterns. On the other hand, the function of justifying the outputs obtained in the radiography interpretation process cannot yet be fulfilled due to the nature of existing machine-learning approaches. Artificial intelligence applications are particularly promising in the field of dentomaxillofacial radiology. Recent research on artificial intelligence in the field of dentomaxillofacial radiology has mostly used algorithms capable of image classification, detection, segmentation, recording creation, and enhancement. AI-based algorithms developed in this field are generally aimed at diagnosis, image analysis, and image quality improvement. A large amount of data is needed to obtain accurate results. In addition, the participation of experienced radiologists is very important to create accurate and consistent datasets. With artificial learning models, it is possible to detect the structures to be examined in radiography, to separate (segmentation) or classify the desired data in the image from other data. These uses of artificial learning models are schematized in Figure 2. There are application examples of these usage areas for specific tasks in dentomaxillofacial radiology. For example, in the field of dentomaxillofacial radiology, various studies have been carried out on artificial intelligence in many different subjects such as dental caries, periodontal diseases, vertical root fractures, periapical pathologies, osteosclerosis, odontogenic cysts and tumors, maxillary sinus pathologies, or diagnosis of temporomandibular joint diseases.

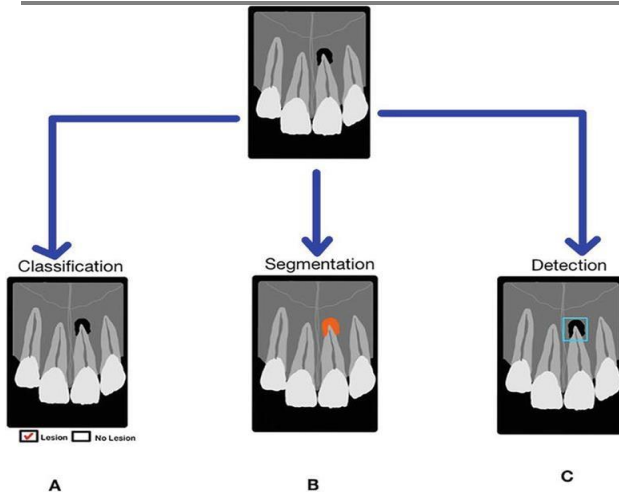


Figure 2.

- (A) The classification (mark as yes or no) of the lesion on the periapical radiograph is schematized.
 (B) The segmentation (orange staining) of the lesion on the periapical radiograph is schematized.
 (C) The detection (blue box) of the lesion on the periapical radiograph is schematized.

In the imaging of maxilla and mandible jaw bones, all existing teeth and surrounding support tissues, panoramic radiographs are the most widely used radiological diagnostic tools. Due to the complex anatomical structure of the region, examined by panoramic radiographs, displaying in 2D may cause superpositions and may cause incorrect and incomplete interpretations. In recent years, these radiographs are among the research data that have an important place in artificial intelligence studies. With a convolutional neural network (CNN) developed to detect benign tumors in the jaws on panoramic radiographs, researchers have developed an algorithm that can diagnose with similar accuracy with specialist dentists. In another study, an algorithm was developed for the diagnosis of osteoporosis by using the same 2D panoramic radiographs and it was stated that the radiographs determined by the algorithm distinguished osteoporosis with excellent accuracy when compared with specialist dentists.

In another study using panoramic radiographs, an AI system was created to detect idiopathic osteosclerosis (IO). As a result of the study results, the sensitivity, precision, and F-measure values were 0.88, 0.83, and 0.86, respectively; the developed AI algorithm has the potential to accurately detect IOs in panoramic radiographs.

In cases clinical examination and 2D radiographs are insufficient, the 3D imaging method commonly used by dentists is cone beam computed tomography (CBCT). In a study in which the detection of periapical lesions with AI algorithms was performed with an accuracy of 92.8%, with an algorithm that detects periapical lesions using CBCT images, the detection and numbering of teeth in volumetric data are also performed.

Radiographic imaging has a very important place in the field of dentistry, both for diagnostic purposes and to provide appropriate treatment. In cases such as implant planning, orthognathic surgery, and surgical applications planned for various pathologies, radiographic images are analyzed as part of treatment planning. The development of artificial intelligence in these areas is highly valuable. Dentomaxillofacial radiologists continue to play an important role in artificial intelligence research, as specialists, who know the basic principles and characteristics of radiographic imaging, can interpret radiographs for various diseases. The data detected by artificial learning will reduce both the rate of inaccurate and incomplete diagnosis and the daily workload of dentists, considering the increasing medical data in radiology practice.

Dentomaxillofacial surgery

It is the branch of dentistry that treats and rehabilitates pathological conditions, trauma, and developmental

anomalies in the mouth, teeth, and jaws. Impacted third molar tooth extraction is one of the most common surgical procedures. One of the most common postoperative complications in third molar surgery is facial swelling.

In a study by a group of researchers, an artificial neural network model was developed to predict the probability of facial swelling after extraction. In 400 extraction procedures performed by a surgeon, surgical factors (individual characteristics of the patients such as age, gender, medical and dental status, the relationship of the third molar with the second molar and ramus, the degree of impaction in the bone, the type of incision, the removal of the tooth in single or multiple pieces, the duration of the procedure, etc.) were determined. While 300 patient data were used in model training, 100 patient data were used in the testing phase. In this study, the estimation accuracy of the probability of swelling was reported to be 98%.

Investigating the ability of CNNs to automatically detect mandible fractures on panoramic radiographs is a current issue in oral and maxillofacial surgery. In a study investigating the detection and classification of mandible fractures (e.g., condyle, coronoid, ramus) on panoramic radiographs, with F1 scores ranging from 0.6 to 0.87, the lowest fixation sensitivity was achieved in coronoid fractures, while the highest sensitivity was obtained in condyle fractures.

Diagnosis and treatment of temporomandibular joint (TMJ) diseases are one of the most difficult issues for dentists. In a study aiming to create an artificial neural network model that is predicted to distinguish between TMJ internal irregularities and normal joint, using TMJ clinical examination findings, the model was trained and tested to detect unilateral/bilateral anterior disc displacements with and without reduction.

The sensitivity and specificity of this developed model range from 37% to 100%. In a new diagnostic tool to accurately detect temporomandibular joint disc displacement with artificial intelligence, proposed by Kao et al., cited the InceptionV3 and DenseNet169 models as the best performing models.

In this study, a two-step procedure was proposed involving the inference of probable location and binary classification of the disc, emphasizing that larger studies using data from different hospitals or countries are needed to fully validate their system. It has been stated that the use of deep learning neural networks in the automatic detection of temporomandibular joint disc displacement from sagittal MRI images are a promising technique to assist radiologists.

In a recent study using magnetic resonance imaging (MRI), in condyle, articular eminence and disc segmentation, the AI model has been reported to have a performance close to that of specialist doctors. In addition, this study also mentioned that CNN-based segmentation models can be a reliable tool to help clinicians define the basic anatomy in TMJ-MRIs. Automatically locating the articular disc and surrounding structures with an AI algorithm has the potential to improve the reliability of TMJ-MRI interpretation and save time.

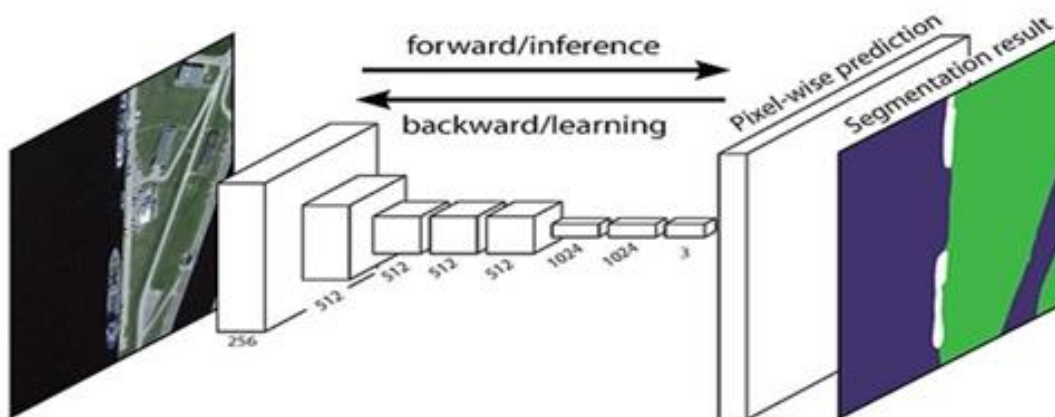


Figure. 3 Segmentation using Deep learning (Le, James, 2024)

A deep learning system called semantic segmentation gives each pixel in an image a label or category. This method is used to find sets of pixels that correspond to different categories. Semantic segmentation, for example, is essential in autonomous vehicles to identify other road characteristics such as pavement, traffic signs, pedestrians, and cars. A logical step on the way from coarse to fine inference is semantic segmentation: The source can be found in categorization, which is the process of predicting an entire input.

The next stage is localization and detection, which gives more details about the classes' spatial locations in addition to the classes themselves. Semantic segmentation produces fine-grained inference by generating dense predictions that infer labels for each pixel, so labeling each pixel with the class of the object or region that surrounds it.

Convolutional neural networks, or CNNs, are an artificial neural network type that is frequently used in deep learning for object and picture recognition and classification. Thus, Deep Learning uses a CNN to identify items in a picture. CNNs are essential for a wide range of applications, including speech recognition in natural language processing, computer vision tasks including segmentation and localization, video analysis, and obstacle recognition for self-driving automobiles. CNNs are highly popular in Deep Learning since they are playing a major role in these rapidly developing and expanding fields.

This model One of the most commonly used methods to eliminate tooth deficiencies is dental implant application. A dental implant is a treatment method developed to replace missing teeth, with long-term success and high survival rates. Although dental implants have high success, mechanical and biological complications can occur. A study was conducted in 1996 using the ML method to classify eight different dental implant systems based on various parameters such as implant diameter, length, and cross-sectional area. In recent years, CNN has been used to classify different implant systems. There are several studies showing that CNN is highly effective in classifying similar shapes of different types of implant systems in dental radiographic images. The quality of the bone area to be implanted is one of the most important factors that directly affect the success of the implant. The sparseness or density of trabecular bone can directly affect the success of implant surgery. Because of the great importance of preoperative determination of trabecular bone morphology, a study group aimed to classify trabecular bone quality. In this study, bone morphology was classified using CBCT images and it was reported that the algorithm made predictions with twice the accuracy of expert dentists in the results obtained. The lack of a gold standard in the classification of the groups and the heterogeneous distribution of the groups in the dataset were stated as the limitations of the study. Despite these limitations in the study, implant planning has been evaluated as a study that contributes to the computer-aided design and production of implant-based prostheses.

Robotic systems have become a part of daily life; although it has been on the agenda for a long time in the field of medicine, minimally invasive surgical procedures such as heart valve repair and gynecological interventions are applied worldwide with the developments in autonomous robot systems. Autonomous robots plan a sequence of actions with AI methods to perform a specific task on their own. Implant surgery is moving toward fully automating implantology upon the implementation of possible robotic applications. On the other hand, due to the inadequacy in the number of studies on this subject, these methods have not been widely used because accuracy and reliability results are not sufficient yet.

Orthognathic surgery is one of the areas where AI applications find their place in oral and maxillofacial surgery. With the widespread use of intraoral scanners, digital imaging in orthognathia has changed radically. Use of AI applications in orthognathic surgery workflow; it can also provide improvements in areas such as obtaining and interpreting maxillofacial imaging, treatment planning, personalized orthodontic and surgical appliances, and treatment follow-up.

Prosthetic dentistry

In functional and esthetic losses caused by deficiencies in teeth and surrounding supporting tissues, it is the

branch of dentistry in which applications are made to restore the lost esthetics and function of the patient by being treated with appropriate prosthetic materials

The preparation and construction stages of prosthetic restorations consist of a series of processes that require high precision, which can be carried out with conventional or digital methods, CAD/CAM (computer-aided design/computer-aided manufacturing), which has been widely used in the production of prosthetic restorations, especially in recent years. It refers to a manufacturing technique that uses computer skills in the design and production of materials required for prosthetic treatment.

Intelligent software is often one of the issues needed to optimize the digital steps of CAD/CAM systems. It is concluded that the novel soft computing optimization process described in a study will increase the efficiency of firms in optimizing machine parameters for industrial processes and will significantly reduce the costs of preparing and adjusting machine processes. AI applications to the dentist in prosthesis production; it helps in designing the best and most esthetic prosthesis by evaluating many variables such as anthropological calculations, face measurements, and patient expectation.

When standard CAD/CAM technologies are applied in implant prosthesis cementation, various problems can arise, such as positional errors, cementation errors, and errors that may occur during occlusal correction with an abutment. In a study aiming to eliminate these errors and time losses, 91% survival and 93% success rate using an AI model in the manufacture of zirconia implants for posterior teeth.

In a study in which the segmentation network structure for tooth preparations was designed with the CNN model, which can automatically extract the margin line by learning the characteristics of the margin line region of the tooth preparation, an accuracy rate of 97.43% was reached.

It has been reported that results with acceptable accuracy were obtained in a study aiming to design a single molar dental prosthesis that mimics the morphology of a natural healthy tooth by learning the tooth characteristics from the remaining teeth thanks to a developed AI algorithm. According to the results of this study, the applicability of artificial intelligence in the design of single-molar dental prostheses has been demonstrated, and it has been emphasized that the accuracy of biomimetic artificial intelligence-designed dental prostheses can be further increased with further training and optimization of the algorithms.

Advances in AI applications promise to autonomously create innovative dental restorations that meet the highest standards in terms of fit, function, and esthetics. Advances in this area will also have a significant impact on orofacial and craniofacial prostheses.

PERIODONTOLOGY

It is a branch of dentistry that examines the health, diseases, diagnosis, and treatment of the soft and hard tissues that support the teeth. Periodontitis is one of the most common oral diseases that can cause alveolar bone loss, tooth mobility, and tooth loss. The diagnosis of periodontitis can be made by clinical examination and radiographic examination of periodontal tissues. Due to their complex structure and low resolution, detecting and analyzing periodontal bone loss (PBL) on radiographs is difficult even for experienced dentists. Therefore, the application of AI for automated assist systems in dental radiographic image data may allow for more reliable and accurate assessments of PBL. Lin et al. developed a computer-aided diagnostic model that can measure the degree of PBL using a hybrid-featured engineering process. Promising results have been shown in these studies, as artificial intelligence models used in various subjects such as classification of periodontal conditions, detection of PBL, and classification of peri-implant diseases and conditions show comparable and even better results than manual analysis of PBL. Microbial dental plaque accumulating on tooth surfaces is one of the main causes of gingival diseases. Therefore, it has an important place in the scoring of periodontal diseases. In one study, a CNN algorithm was developed to classify the amount of microbial dental plaque in intraoral photographs obtained with a Quantitative Light Effect Fluorescence (QLF) camera. It has been reported that

the model that performs high in the training set has lower success in the test set. On the other hand, although the intra-observer and interobserver agreement of dentists was high in manual QLF analyzes, it was emphasized that this CNN model was superior in terms of cost and time when the number of images was high. We predict that artificial intelligence in dentistry will continue to maintain its popularity in the field of periodontology and will show greater developments in the coming years.

Orthodontics

It is the branch of dentistry that diagnoses and treats the placement irregularities of the teeth and the development and position disorders of the jaws. In a study, the extraction requirement before orthodontic treatment was modeled using an artificial neural network, and it was concluded that the accuracy increased significantly, especially as a result of the use of the decision-making model with pretraining.

In a study to estimate the mesiodistal widths of unerupted teeth, the deep learning model (DL) used and the Moyers table (MT) were compared. According to the results obtained in the study, the prediction performance of the DL system for unerupted mandibular canine and premolar teeth was at an acceptable level with an accuracy of 49.5%. It is thought that AI models may offer a potential alternative to existing methods in estimating erupted tooth size and provide diagnostic support for mixed dentition analysis in tooth patterns.

Cephalometric image analysis is widely used to evaluate the skeletal anatomy of the human skull for treatment planning and evaluation of treatment outcomes. Many anatomical landmarks usually need to be defined manually for cephalometric analysis. AI technology has been developed in automatic cephalometric anatomical points and skeletal relationship classification to reduce the burden on the clinician and save time.

The developed AI models allowed not only to identify anatomical points, but also to measure or analyze anatomical points in cephalograms. In a study conducted in 2015 using knowledge-based algorithms, an AI model capable of automatic cephalometric measurement has been developed. According to the results of this study, there was no significant difference between automatic and manual measurements.

The highly successful results demonstrated by fully automated cephalometric analysis systems have demonstrated the potential of AI application as a cephalometric orthodontic diagnostic tool.

In a recent CNN-based AI study, Sella Turcica segmentation and classification using CBCT images yielded results with a high percentage of accuracy. Using artificial intelligence algorithms, it can be predicted that the detection of anatomical signs with orthodontic importance will save orthodontists time and facilitate diagnosis.

Endodontics

It is a branch of dentistry that consumes all components of pulpal and periapical pathologies from their etiology to their treatment. Areas such as anatomical variations of root canals, canal shaping techniques, and materials used in treatments are some of the topics that are researched and continue to be developed in endodontics. The role of artificial intelligence in the diagnosis and treatment planning of diseases in endodontics is increasing.

Due to the clinical examination of the root canal morphology, radiological imaging is closely related to endodontic treatment. Panoramic radiographs, which are 2D imaging methods, may be insufficient to understand root canal morphology.

In a study aimed at estimating the number of distal roots of mandibular first molars, which are single in the majority of the population and sometimes may have accessory canals, on panoramic radiographs, two separate CNN algorithms were created and their estimation performances were compared. There was no significant difference between the performances of the two models, and it was reported that both had high accessory root

discrimination performance on panoramic radiographs.

Determining the location of the root canal openings is one of the important stages of root canal treatment. Clinicians use magnifying glasses or operating microscopes to detect these small canal entrances. In a study for the location and classification of canal orifices, researchers reported that the model detected canal orifices with 94% accuracy and differentiated upper and lower molars with 90% accuracy. The study indicates that root canals can be detected and classified in real-time via software.

One of the main stages that determine the success of root canal treatment is the determination of the working length of the canal. In another endodontic study, researchers tried a new approach to reduce the error in the step of determining canal working length on radiographs. In the experimental setup as in vitro, the extracted teeth with access cavities were placed in the extraction sockets of the cadavers, and intraoral films were taken by reaching the root tip with the canal tool. Then, two endodontists examined the apex of the teeth with a microscope and the apical foramen with radiographs, and the working length was divided into three classes as “short, in situ and long” according to the position of the canal file. The reliability of the measurement of the working length was questioned by training the model with tooth length and approximate and detailed images. It was concluded that the position of the file can be reliably determined using AI.

Correct determination of working length is very important for successful root canal treatment results. A method used to evaluate working length, radiography, digital tactile sense, electronic apex locators, patient response to a paper point inserted into the root canal system, and CBCT imaging. Clinical dentists most commonly prefer radiography and electronic apex locators. The clarity of the image in digital radiography and several other factors that affect how radiographic interpretations are made are essential for the correct interpretation of the anatomy of the root canal system. Otherwise, it may lead to misdiagnosis. Saghiri et al. used a human cadaver model to replicate a clinical setting and examined the accuracy of run-length assessment by an artificial neural network. Compared to the actual working length measurements, where the stereomicroscope was used as the gold standard after tooth extraction, the model was more accurate than the determinations of the endodontists, and it was concluded that neural networks are an accurate method for determining the working length.

Restorative dentistry

It is a branch of dentistry that treats structure and deformities caused by dental hard tissue (enamel, dentin) diseases with protective, restorative, and esthetic methods. The fact that dental caries is still one of the most common diseases in the world causes studies in this field to be among the popular research topics. The most commonly used method to support the clinical examination in the diagnosis of dental caries is radiological examination.

AI can provide assistance in recognizing some pathologies such as proximal caries and periapical pathologies that cannot be detected on radiographs due to noise, artifact, and low contrast in images. There are many studies that have achieved high-performance results (86–97% accuracy) in the classification of dental caries on radiographs. Different DL-based CNN methods have also been developed to detect dental caries on periapical radiographs.

Detection of caries that arise on the chewing surfaces (occlusal) of the teeth and have not yet progressed to the interfaces can be successfully made by clinical examination. The high enamel density due to the anatomy of the region may cause the demineralization area formed by caries to remain hidden in the radiography. In a study, a deep learning model was designed to diagnose caries in photographs of occlusal caries recorded with an intraoral camera. Since the samples of intraoral photographs obtained in vivo are low in number, the model has been strengthened with data augmentation and transfer learning methods. In another pilot study, the transillumination method used for caries diagnosis was examined. Although the diagnostic performance of the designed CNN algorithm is not bad, the sensitivity and specificity tests indicate that it is not yet reliable enough to be used in clinical practice.

Pediatric dentistry

It is a branch of dentistry that deals with the examination and treatment of first and permanent teeth in infants, children, and young adults.

In a study on the assessment of oral health in children using machine learning, researchers developed an algorithm for assessing children's oral health status and treatment needs. Oral health status and treatment needs were estimated by processing the data obtained through a questionnaire prepared for children and their parents with machine learning algorithms. It has been proposed as a method that can be used for screening purposes in schools.

In the literature, there is a study stating that software that can predict individual pain level and analgesia responses for postoperative pain management has been developed by using artificial intelligence models in the field of anesthesia.

Assistive tools have been developed to facilitate communication in age groups who have difficulty in describing their pain, in children with it is difficult to communicate, and in individuals with disabilities.

One of the areas studied extensively by the European Academy of Pediatric Dentistry (EAPD) is molar-incisor-hypomineralization (MIH).

In the study published in 2022, aiming to update the current European Academy of Pediatric Dentistry (EAPD) 2010 policy document on "Best Clinical Practice guideline for clinicians dealing with children presenting with molar-incisors-hypomineralization (MIH);" MIH etiology has a multifactorial etiology including systemic medical and genetic factors, and more focused laboratory research and prospective clinical studies are needed to elucidate additional factors. Successful prevention and treatment options have been researched and established. Regarding treatment options, there are many alternative options such as composite restorations, metal crowns, and laboratory indirect restorations.

There are factors depending on the severity of the defects and the age of the patient that play a role in the selection of the appropriate treatment. A deep learning-based convolutional neural network (CNN) was developed for the automatic detection and classification of teeth affected by MIH in intraoral photographs. It could accurately categorize teeth with MIH with an overall diagnostic accuracy of 95.2% .

The dental plaque that causes many oral diseases (e.g., caries, gingivitis, and periodontitis) is one of the important issues in protecting the oral and dental health of children . Dental plaque consists of bacterial masses on tooth surfaces; dental plaque is often difficult to distinguish, as these masses usually occur at the gingival margin and in the interproximal areas .

A deep learning-based artificial intelligence model has been used as a current approach to detect plaque in primary teeth. As a result of plaque detection examinations on intraoral photographs; it was stated that there was no significant difference between the developed AI model and the pediatric dentist in diagnosing dental plaque in deciduous teeth, and the AI model showed clinically acceptable performance in detecting dental plaque in primary teeth compared to an experienced pediatric dentist .

Determining the most appropriate treatment procedure for primary teeth in pediatric dentistry is directly related to the presence or absence of permanent tooth germ . Developmentally missing or extra permanent teeth are an important issue in the selection of endodontic or restorative rehabilitation for primary teeth. Evaluation of the performance of the deep learning system for permanent tooth germ detection in panoramic radiographs is among the subjects studied. A total of 4518 panoramic radiographs of children aged 5–13 were used in a study addressing this issue. Permanent tooth germs were detected with a deep learning-based approach in panoramic X-rays, using the YOLOv4 model, with an extraction time of 90 ms, with an average precision of 94.16% and

an F1 value of 0.90, with a high level of significance. In this way, it is thought by researchers that it can facilitate the early diagnosis of missing teeth or supernumerary teeth and help dentists find more accurate treatment options while saving time and effort.

Forensic dentistry

Determination of gender and age from skeletal remains is an important issue in forensic studies. Age estimation is an important aid, from identifying individuals and injured persons in natural disasters to resolving forensic cases. Teeth are hard and not easily destroyed tissues in the human body, and their shape remains unchanged and intact after the individual dies. For this reason, forensic dentistry has an important place in identification. Comparison of tooth numbers and shapes in a dental radiograph taken from a cadaver with previous records is one of the methods used effectively. In forensic medicine literature, teeth have proven to be a meaningful tool in identifying people. Studies suggesting that neural networks can serve as a reliable method for determining age and gender also indicate that more research is needed to determine their accuracy. In one of the studies on this subject, it was found that neural networks showed 95% accuracy in distinguishing gender in the anthropological skull. Successful results have also been obtained in studies using trained neural networks to calculate skeletal age from hand-wrist X-rays. AI algorithms can also be used to analyze bite marks and predict mandible morphology.

In a study for age and gender estimation, 1142 digital X-ray images, 80% of it were used for educational purposes and the remaining 20% of the dental images were used for test cases, achieving 96% accuracy.

In a recent study, Patil et al. discussed the use of root length in age determination, which has not been researched until that time. In the study, it was stated that the Deep Learning model outperformed the Machine Learning model and the right third molar tooth mesial root length is a good indicator of age. It is emphasized that the training dataset should be expanded to include more radiographs from multiple sources in order to further refine, diversify, and bring the algorithms into clinical practice.

Artificial Intelligence in dentistry education

Artificial intelligence applications, which aim to change the traditional structure of dental education in faculties, are still an area open to research. Intelligent teaching systems provide new opportunities for education in universities, improving the quality of learning in dentistry education. It is obvious that learning, teaching, measurement-evaluation, and feedback methods have changed and improved. Today, many technological developments supported by artificial intelligence are rapidly taking place in the challenging education process of dentistry. Clinical decision support systems are effective information technology that reduces clinical errors, helps dentists make better medical decisions, and thus increases the quality of treatment. This technology holds the strongest position among promising fields of study, as it can help inexperienced dentists and students to form stronger convictions about the treatment process.

The field of intelligent teaching systems has made significant progress today. AI applications are often used to create scenarios that mimic clinical work on patients and minimize any educational hazards. It is observed that the preclinical virtual patient feedback given to the students has improved significantly.

The main goal is to create high-quality learning environments, allowing students to evaluate their work and compare it to the ideal one. Numerous studies have been conducted on the effectiveness of these systems, and it has been shown that students develop a competency-based skill level more quickly with these systems than with traditional simulator units.

Dentistry students receive preclinical training to develop their manipulative skills before they come into contact with the patient. In the skill development studies on the traditional phantom models used during this training, the student learns by receiving feedback from the trainer. Instead, when the same practices are experienced with

a virtual patient under the supervision of a trainer, the feedback that the virtual patient provides to students can improve the quality of learning. Studies examining the effectiveness of these systems have shown that students reach the expected skill level more quickly.

Today, along with the development of robotic models that can verbalize pain, move the head with pain, make jaw and tongue movements, and simulate functions such as bleeding and saliva flow. In dentistry education, the use of robotic models has increased in preclinical laboratories to develop students' basic motor skills. Increasing studies in this field and decreasing software and hardware costs of robotic instruments will enable more widespread use of robotic applications in dental faculties. In AI applications in the field of education, as well as improving education, the inclusion of AI-based subjects in the curriculum is also a very important issue.

Considering the ongoing research in almost every branch and the applications that are starting to come into use, it is clearly revealed that dental candidates will be both users and developers of these applications in the future. Introducing dentistry students to basic AI terminology and working principles will contribute to the advancement of this field developed with human intelligence.

CONCLUSION AND PROSPECTS

Hybrid intelligence is a term that refers to the combination of human and machine intelligence with the aim of advancing human intelligence. It is based on the principle that humans can work in harmony with artificial intelligence to solve difficult problems. The use of a newly developed hybrid intelligent image fusion method to combine multimodal images for better diagnosis and treatment planning will become widespread.

The diagnostic performance of AI models varies between the different algorithms used. Although the AI models used have high success rates, it is still necessary to verify the generalizability and reliability of these models using adequate, representative images from multiple institutions before using these models in clinical applications.

Artificial intelligence digital systems have indisputably changed the future predictions and development direction of dentistry. It is obvious that computer-based neural networks play a supporting role in the decision-making and minimizing of errors during the execution of dental treatment planning for dentists, but it should be noted that more research and application are needed.

In short, although there are both technical and ethical difficulties in artificial intelligence, the fact that it is a very open field for development and progress makes artificial intelligence worth researching.

The risks are especially high in the health field. There are great concerns about data protection, data security, and the transfer of critical medical decisions to computers. However, artificial intelligence has the potential to revolutionize both healthcare and dentistry. In the upcoming period, it seems inevitable that artificial intelligence and dentists must work together in cooperation. It is becoming a necessity of the age for dentists to follow current developments and integrate them into their clinical lives. On the other hand, the support of dentists is absolutely needed in order to carry the achieved developments further.

REFERENCES

1. Khanagar SB, Vishwanathaiah S, Naik S. Application and performance of artificial intelligence technology in forensic odontology - A systematic review. *Legal Medicine* (Tokyo, Japan).
2. Santosh KC, Pradeep N, Goel V, Ranjan R, Pandey E, Shukla PK. Machine Learning Techniques for Human Age and Gender Identification Based on Teeth X-Ray Images. *Journal of Healthcare Engineering*.
3. Patil V, Saxena J, Vineetha R, Paul R, Shetty DK, Sharma S. Age assessment through root lengths of mandibular second and third permanent molars using machine learning and artificial neural networks. *Journal of Imaging*.

4. ANSDIT (American National Standard Dictionary of Information Technology. New York: Springer; 1996 Grudin J. Turing maturation: Separation of artificial intelligence and human-computer interaction. Interactions
5. Richardson K. Genes, Brains, and Human Potential: The Science and Ideology of Intelligence. Columbia University Press; 2017
6. Lebedev MA, Nicolelis MA. Brain-machine interfaces: From basic science to neuroprostheses and neurorehabilitation. Physiological Reviews. 2017