Cardiac Evaluation in Ischaemic Stroke Revealing an Unrecognized Myocardial Infarction and Left Ventricular Thrombus A Case Report and Literature Review

Z. Bennoui[1]*, N. Annane[2]

[1]*Department of Cardiology, Tipaza Hospital, West Algiers, Algeria

[2]Department of Surgery, Tipaza Hospital, West Algiers, Algeria

***Corresponding Author**

DOI: https://doi.org/10.51244/IJRSI.2026.1311000046

Received: 04 November 2026; Accepted: 09 November 2026; Published: 21 November 2026

ABSTRACT

Background: Cardiac assessment is an essential component of the evaluation of ischaemic stroke. Beyond detecting arrhythmias, electrocardiography may identify evidence of previously unrecognized myocardial disease and prompt echocardiographic investigation of a potential embolic source.

Case presentation: A 70-year-old man with hypertension, diabetes mellitus and a 30-pack-year smoking history presented 12 hours after the onset of dysarthria and left hemiparesis. His National Institutes of Health Stroke Scale (NIHSS) score was 5. Electrocardiography showed anterior QS complexes and ST-segment elevation. Directed questioning revealed untreated chest discomfort approximately one month earlier. Transthoracic echocardiography demonstrated apical akinesia with reported aneurysmal remodelling and an adherent thrombus measuring 20 × 15 mm, despite a left ventricular ejection fraction of 57 %. Brain computed tomography showed an ischaemic lesion described as a lacune in the right middle cerebral artery territory, without haemorrhage. Following neurological consultation and a repeat brain CT excluding haemorrhagic transformation, continuous intravenous unfractionated heparin was initiated 72 hours after stroke onset at 500 IU/kg/24 hours for five days, followed by rivaroxaban 20 mg once daily. The NIHSS score improved to 2 at discharge. At seven months after discharge, the thrombus measured 10 × 5 mm under continued rivaroxaban, with no reported haemorrhagic event.

Conclusion: This case illustrates the diagnostic value of cardiac assessment in ischaemic stroke. Electrocardiographic evidence of myocardial injury or prior infarction should prompt appropriate cardiac investigation, including echocardiography to assess regional ventricular function and search for intracardiac thrombus. Preserved global ejection fraction does not exclude a clinically important apical lesion. The coexistence of ventricular thrombus and stroke does not, however, establish a cardioembolic mechanism.

Keywords: Ischemic Stroke; Myocardial Infarction; Electrocardiography; Echocardiography; Thrombosis; Anticoagulants.

INTRODUCTION

The evaluation of ischaemic stroke includes assessment of potential cardiac sources and associated cardiovascular disease. A baseline electrocardiogram (ECG) is recommended during the initial assessment, without delaying time-sensitive cerebral reperfusion treatment [1]. Its interpretation should extend beyond the detection of atrial fibrillation to include abnormalities suggestive of myocardial ischaemia or previous infarction. These findings can guide further investigation and influence secondary prevention [1,2].

ISSN No. 2321-2705 | DOI: 10.51244/IJRSI |Volume XIII Issue XI November 2026

Transthoracic echocardiography (TTE) can identify structural abnormalities that are not apparent on clinical examination, including regional ventricular dysfunction and intracavitary thrombus. Left ventricular thrombus is a recognized complication of myocardial infarction and may be present despite preserved global systolic function [3]. We describe a patient in whom cardiac assessment during an ischaemic stroke admission identified a clinically diagnosed, previously unrecognized myocardial infarction with apical thrombus. The accompanying narrative literature review focuses on the diagnostic progression from ECG to echocardiography and its implications for management.

Case Presentation

Clinical Presentation

A 70-year-old man presented 12 hours after the onset of dysarthria and left hemiparesis. His medical history included hypertension and diabetes mellitus of five years' duration, treated with valsartan/hydrochlorothiazide 80/12.5 mg and metformin, respectively. His smoking exposure was 30 pack-years. He had no clinical signs of heart failure. Blood pressure was 120/70 mmHg, peripheral pulses were palpable, and the admission NIHSS score was 5.

Directed questioning identified an episode of chest discomfort approximately one month earlier. He described brief, intermittent, low-intensity central burning without radiation, occurring at rest after a family conflict and associated with an episode of vomiting. The symptoms resolved spontaneously, and he had not sought medical attention.

Cardiac and Neurological Investigations

The ECG showed sinus rhythm at approximately 80 beats/min, anterior QS complexes and ST-segment elevation in the same distribution. In conjunction with the preceding chest discomfort and regional apical dysfunction, these findings supported the clinical diagnosis of a previously unrecognized anterior myocardial infarction (Figure 1). Admission troponin was reported as negative. Haemoglobin, platelet count, renal function and lipid measurements were reported to be within laboratory reference ranges.

TTE demonstrated an akinetic apex with reported aneurysmal remodelling and a thrombus measuring 20 × 15 mm adherent to the apical wall. Global left ventricular ejection fraction was 57%, measured using Simpson's method. Estimated left ventricular filling pressures were not elevated, and no other significant echocardiographic abnormality was reported (Figure 2).

Brain computed tomography demonstrated an ischaemic lesion described as a lacune in the right middle cerebral artery territory, without haemorrhage.

Doppler examination of the supra-aortic vessels showed intimal thickening without stenosis. Forty-eight-hour Holter monitoring detected no atrial fibrillation, ventricular ectopy or ventricular tachycardia.

Taken together, the antecedent chest discomfort, anterior QS complexes and regional apical akinesia with aneurysmal remodelling supported the clinical diagnosis of a previously unrecognized anterior myocardial infarction complicated by left ventricular thrombus. A cardioembolic mechanism was favoured clinically in view of the large ventricular thrombus and the absence of supra-aortic arterial stenosis or atrial fibrillation. However, the reported lacunar appearance of the cerebral lesion also raised the possibility of small-vessel disease. Acute stroke management was prioritised.

Coronary angiography was not performed during the admission in the context of the delayed presentation of the myocardial event. Coronary anatomy and myocardial scar characterisation by cardiac magnetic resonance were therefore unavailable.

Treatment and Follow Up

Following neurological consultation, continuous intravenous unfractionated heparin was initiated 72 hours after stroke onset, after repeat brain computed tomography had excluded haemorrhagic transformation. The admission NIHSS score of 5 was taken into account when determining treatment timing. The indication for anticoagulation was the documented left ventricular thrombus. Unfractionated heparin was administered at 500 IU/kg/24 hours for five days. Monitoring included activated partial thromboplastin time (aPTT), with a target ratio of 2–3 times the control value, and platelet counts to screen for heparin-induced thrombocytopenia. Treatment was subsequently switched to rivaroxaban (Trombix®) 20 mg once daily. Additional treatment included a statin, bisoprolol and ramipril. Antiplatelet therapy was not prescribed; the recorded rationale was the interval since the myocardial infarction and the negative admission troponin.

The NIHSS score improved from 5 at admission to 2 at discharge. No bleeding or recurrent embolic event was reported during hospitalisation. An early echocardiographic reassessment approximately one week after the initial examination showed persistence of the thrombus measuring 15 × 10 mm adherent to the apical wall.

Rivaroxaban was continued through the follow-up assessment seven months after discharge. At that time, echocardiography showed a residual apical thrombus measuring 10 × 5 mm, indicating partial regression compared with the initial dimensions. No haemorrhagic event was reported during this period. These findings describe the subsequent course; the principal clinical contribution of the case is the identification of previously unrecognized cardiac disease during stroke evaluation.

Table 1. Clinical timeline

Time point	Clinical findings or management
Approximately one month before stroke	Self-limited chest discomfort with vomiting; no medical consultation.
Admission, 12 hours after neurological onset	Dysarthria and left hemiparesis; NIHSS 5. Clinical and ECG findings supported prior anterior infarction; TTE showed apical thrombus 20 × 15 mm and LVEF 57%.
72 hours after stroke onset and subsequent treatment	Repeat brain CT excluded haemorrhagic transformation. Continuous intravenous unfractionated heparin 500 IU/kg/24 hours was initiated for five days, followed by rivaroxaban 20 mg once daily. Monitoring: aPTT target ratio 2–3 times control and platelet counts.
Approximately one week after initial TTE	Thrombus remained visible; repeat dimensions were not documented.
Discharge	NIHSS 2; no reported in-hospital bleeding or recurrent embolism.
Seven months after discharge	Thrombus 10 × 5 mm under continued rivaroxaban; no reported haemorrhagic event.

DISCUSSION

Cardiac Assessment as Part of the Stroke Investigation

A neurological presentation can be the first occasion on which an underlying cardiac disorder is recognized. In this case, the absence of heart failure did not predict the absence of a ventricular lesion. The ECG provided a cardiac diagnostic clue, and echocardiography established the regional structural abnormality and associated thrombus. The practical lesson is that cardiac evaluation should not be restricted to patients who report current chest pain or have an abnormal cardiovascular examination.

Initial cardiac assessment combines history, examination and ECG with rhythm surveillance and additional testing as indicated. The 2021 AHA/ASA secondary prevention guideline recommends ECG assessment for atrial fibrillation, atrial flutter and concomitant cardiac disease, and supports echocardiography when

ISSN No. 2321-2705 | DOI: 10.51244/IJRSI |Volume XIII Issue XI November 2026

investigating a possible cardiac embolic source in cryptogenic stroke [2]. This approach distinguishes routine initial cardiac assessment from indiscriminate use of every cardiac imaging modality.

Electrocardiographic Clues Beyond Atrial Fibrillation

An ECG obtained during stroke assessment should also be examined for pathological Q or QS waves, poor anterior R-wave progression and ST–T abnormalities. Such findings can suggest a prior myocardial event or raise concern for ongoing ischaemia. They require interpretation with the clinical history, biomarkers and imaging: a single ECG cannot reliably establish the timing or mechanism of myocardial injury [1,4,5].

Here, the anterior QS complexes and apical dysfunction were consistent with a prior anterior infarction. The delayed negative troponin did not exclude an event approximately one month earlier. The universal definition of myocardial infarction recognizes that prior infarction may be identified through appropriate ECG or imaging evidence after alternative causes have been considered [5]. ST elevation can accompany ventricular aneurysmal remodelling; the available tracing alone did not demonstrate that the elevation was persistent over time.

The preceding symptoms are better described directly than labelled “atypical”. Brief burning discomfort and spontaneous resolution do not establish a non-cardiac cause, particularly in a patient with several cardiovascular risk factors [4]. In this case, the clinical history, anterior QS complexes and regional apical akinesia with aneurysmal remodelling were concordant with prior anterior infarction. Accordingly, myocardial infarction was retained as the clinical diagnosis rather than excluded or downgraded solely because angiography and cardiac magnetic resonance were not performed [5].

Echocardiography After an Abnormal ECG

ECG evidence suggesting myocardial disease provides a clear reason to assess ventricular structure and function. TTE should examine regional wall motion and the ventricular apex as well as global ejection fraction. In this patient, the clinically relevant finding was a local apical abnormality associated with thrombus despite an overall ejection fraction of 57%. A global measurement alone would have incompletely characterized the cardiac substrate.

Apical akinesia favours local blood stasis, while infarct-related endocardial injury can facilitate thrombus formation [3]. An apical mass should be assessed in multiple views, with documentation of its size, attachment and mobility. When routine TTE is inconclusive or the apex is poorly visualized, contrast echocardiography or cardiac magnetic resonance can improve diagnostic confidence [3,6]. Magnetic resonance also provides myocardial tissue characterisation.

A normal ECG should not be used to exclude a structural cardiac embolic source. Echocardiographic investigation may still be appropriate when the stroke mechanism remains unexplained or when other clinical findings suggest cardiac disease [2]. The diagnostic sequence illustrated here is therefore a useful route to detection, not a requirement that every echocardiogram be preceded by an abnormal ECG.

Finding a Potential Embolic Source Without Overstating Causality

The ventricular thrombus was clinically important regardless of whether it caused the presenting stroke. Its presence warranted a specific management assessment, but coexistence is not proof of embolism. The cerebral lesion was described as a lacune, and the patient had hypertension and diabetes, both compatible with a competing small-vessel mechanism. The exact lesion location, size and evidence of acuity would be needed to refine aetiological attribution.

The large ventricular thrombus and absence of supra-aortic arterial stenosis led the treating team to favour a cardioembolic mechanism. Forty-eight-hour Holter monitoring without atrial fibrillation also cannot exclude intermittent arrhythmia. A ventricular embolic source was therefore clinically favoured, while the lacunar appearance of the lesion and competing vascular risk factors prevented definitive causal attribution.

ISSN No. 2321-2705 | DOI: 10.51244/IJRSI |Volume XIII Issue XI November 2026

Management Implications of Detecting Ventricular Thrombus

Detection of ventricular thrombus changed the treatment discussion. The AHA scientific statement supports oral anticoagulation for post-infarction left ventricular thrombus, generally for approximately three months, and considers direct oral anticoagulants a reasonable alternative to warfarin in appropriate patients [3]. ESC guidance considers a 3–6-month course, with subsequent decisions informed by repeat imaging, bleeding risk and associated antiplatelet requirements [7].

Rivaroxaban has also been evaluated directly in post-infarction left ventricular thrombus. In the open-label RIVAWAR trial, 261 patients were randomised to rivaroxaban 20 mg once daily or warfarin with a target INR of 2–3 for 12 weeks. Thrombus resolution at 12 weeks was similar (95.8% and 96.6%, respectively) [8]. These findings support rivaroxaban as an alternative in selected patients, but do not establish the optimal timing of anticoagulation after an acute cerebral infarction or validate a preceding five-day heparin course. The trial population and concomitant antiplatelet treatment also differed from this case.

The timing of anticoagulation after ischaemic stroke requires consideration of neurological severity, infarct extent, cerebral imaging and the risk of recurrent embolism. The 2026 AHA/ASA guideline identifies intracardiac thrombi as a subgroup in which early anticoagulation may warrant individual consideration, while acknowledging limited evidence [1]. The EHRA practical guide suggests that oral anticoagulation may be initiated from day 3 after a mild atrial-fibrillation-associated stroke when infarct size is not expected to substantially increase haemorrhagic transformation risk. It emphasises brain imaging and individual assessment, but does not establish a day-3 unfractionated heparin protocol and advises against routine heparin bridging before a direct oral anticoagulant in that setting [9]. ELAN and OPTIMAS provide evidence on the timing of direct oral anticoagulants after stroke with atrial fibrillation; their findings cannot directly validate therapeutic heparin for ventricular thrombus in sinus rhythm [10,11].

Balancing Recurrent Embolism and Haemorrhagic Transformation

Deferring anticoagulation does not remove clinical risk: a persistent left ventricular thrombus remains a potential source of further cerebral or systemic embolism. The AHA scientific statement cites an approximate annual stroke or systemic embolisation rate of 10–15% for untreated left ventricular thrombus [3]. This historical population estimate cannot be converted into an individual 72-hour recurrence probability, but supports avoiding an unnecessary prolonged delay once cerebral bleeding risk has been assessed. In this patient, the 20 × 15 mm thrombus and associated apical akinesia provided a continuing embolic substrate despite preserved global ejection fraction. Prevention of a further embolic event was therefore a treatment objective, even though the mechanism of the presenting stroke was not definitively established.

The competing haemorrhagic risk originates in ischaemic injury to the cerebral microvasculature. Arterial occlusion reduces oxygen and glucose delivery, causing ATP depletion, ion-pump failure and intracellular sodium and water accumulation (cytotoxic oedema). Glutamate-mediated excitotoxicity, calcium overload and oxidative stress amplify cellular injury. Endothelial dysfunction and inflammation then compromise the neurovascular unit: matrix metalloproteinases, including MMP-9, degrade endothelial tight junctions and the vascular basement membrane. Increased blood–brain barrier permeability permits plasma leakage and vasogenic oedema; more severe microvascular damage allows erythrocyte extravasation [12,13]. Restoration of blood flow through spontaneous recanalisation, collateral circulation or therapeutic reperfusion can expose these damaged vessels to renewed flow and pressure. Haemorrhagic transformation can therefore occur without thrombolysis or anticoagulation. Anticoagulation does not initiate the ischaemic vascular injury, but impaired haemostasis may favour the development or expansion of bleeding in the injured territory [12,13].

Haemorrhagic transformation ranges from petechial haemorrhagic infarction, often without mass effect, to a parenchymal haematoma that may cause neurological deterioration. It is commonly detected during the first few days but can also occur later [13]. In one cohort investigating spontaneous transformation, the median detection time was 3 days (interquartile range, 2–6 days) [14]. These are detection times rather than precise biological onset times. Accordingly, a CT scan without haemorrhage at 72 hours documents the imaging status at that time

but cannot exclude subsequent transformation. This temporal overlap between continuing embolic risk and evolving microvascular fragility explains why anticoagulation timing requires individual assessment.

The decision thus required balancing the ongoing embolic risk from the ventricular thrombus against the potential severity of intracranial bleeding. The admission NIHSS score of 5, neurological consultation and absence of haemorrhagic transformation on repeat CT informed the decision to start anticoagulation at 72 hours. This was an individualised clinical judgement rather than a universally safe time threshold. Neurological severity should be considered together with infarct extent and imaging findings, since a low NIHSS alone does not quantify haemorrhagic risk [1,9]. The absence of reported bleeding or recurrent embolism during hospitalisation describes the observed outcome but cannot prove that this timing was superior to an alternative strategy.

During unfractionated heparin treatment, monitoring included aPTT with a target ratio of 2–3 times the control value and platelet counts for heparin-induced thrombocytopenia surveillance. The reported target is distinct from measured serial results and does not establish time within the therapeutic range. At seven months, reduction of the thrombus from 20 × 15 mm to 10 × 5 mm represented partial regression. This single-patient course cannot establish comparative efficacy. Persistent thrombus warrants reassessment of its morphology, the ventricular substrate and bleeding risk when deciding whether to continue or modify anticoagulation [3,7].

The decision not to prescribe antiplatelet therapy should be distinguished from its recorded justification. A negative troponin weeks after infarction is not, by itself, sufficient to determine the antiplatelet strategy. Coronary assessment should likewise be distinguished from routine late reperfusion: ESC guidance advises against routine intervention on an occluded infarct-related artery more than 48 hours after symptom onset in stable patients without persistent symptoms, but does not preclude subsequent diagnostic angiography [7]. An infarction more than one week old is therefore not a general reason to exclude coronary investigation, and viability testing is not universally required before angiography. Subsequent investigation and antithrombotic therapy should be individualised according to coronary indications and bleeding risk.

CONCLUSION

Cardiac assessment should be an integral part of the evaluation of ischaemic stroke, even when cardiac symptoms and signs of heart failure are absent. ECG interpretation should extend beyond rhythm analysis to look for evidence of myocardial ischaemia or prior infarction. Such abnormalities should prompt appropriate cardiac investigation, including echocardiography to assess regional function and search for intracardiac thrombus. This case demonstrates how that approach can reveal clinically actionable apical disease despite preserved global ejection fraction. The central lesson is the diagnostic contribution of cardiac evaluation, while the cause of the cerebral event must remain subject to a complete aetiological assessment.

Learning Points

- Obtain and interpret an ECG as part of the initial assessment of ischaemic stroke, without delaying indicated cerebral reperfusion treatment.
- Look beyond atrial fibrillation for ECG evidence of myocardial ischaemia or previous infarction.
- Use echocardiography when cardiac disease or a potential cardiac embolic source is suspected, assessing regional wall motion and the apex as well as global ejection fraction.
- An intracardiac thrombus can change management, but its presence does not by itself prove the mechanism of the stroke.

Declarations

Patient consent: Written informed consent was obtained from the patient for publication of the clinical data and accompanying images.

Conflicts of interest: The authors declare no conflicts of interest.

Funding: This work received no specific grant from any funding agency.

Author contributions: Professor Annane contributed to the critical revision of the manuscript.

REFERENCES

1. Prabhakaran S, Gonzalez NR, Zachrison KS, et al. 2026 Guideline for the early management of patients with acute ischemic stroke: a guideline from the American Heart Association/American Stroke Association. Stroke. 2026;57(8):e316–e436. doi:10.1161/STR.0000000000000513.
2. Kleindorfer DO, Towfighi A, Chaturvedi S, et al. 2021 Guideline for the Prevention of Stroke in Patients With Stroke and Transient Ischemic Attack: A Guideline From the American Heart Association/American Stroke Association. Stroke. 2021;52(7):e364–e467. doi:10.1161/STR.0000000000000375.
3. Levine GN, McEvoy JW, Fang JC, et al. Management of patients at risk for and with left ventricular thrombus: a scientific statement from the American Heart Association. Circulation. 2022;146(15):e205–e223. doi:10.1161/CIR.0000000000001092.
4. Gulati M, Levy PD, Mukherjee D, et al. 2021 AHA/ACC/ASE/CHEST/SAEM/SCCT/SCMR guideline for the evaluation and diagnosis of chest pain: a report of the American College of Cardiology/American Heart Association Joint Committee on Clinical Practice Guidelines. J Am Coll Cardiol. 2021;78(22):e187–e285. doi:10.1016/j.jacc.2021.07.053.
5. Thygesen K, Alpert JS, Jaffe AS, et al. Fourth universal definition of myocardial infarction (2018). Eur Heart J. 2019;40(3):237–269. doi:10.1093/eurheartj/ehy462.
6. Roifman I, Connelly KA, Wright GA, Wijeysundera HC. Echocardiography vs. cardiac magnetic resonance imaging for the diagnosis of left ventricular thrombus: a systematic review. Can J Cardiol. 2015;31(6):785–791. doi:10.1016/j.cjca.2015.01.011.
7. Byrne RA, Rossello X, Coughlan JJ, et al. 2023 ESC Guidelines for the management of acute coronary syndromes. Eur Heart J. 2023;44(38):3720–3826. doi:10.1093/eurheartj/ehad191.
8. Shah JA, Hussain J, Ahmed B, et al. Rivaroxaban vs warfarin in acute left ventricular thrombus following myocardial infarction: RIVAWAR, an open-label RCT. JACC Adv. 2025;4(8):101978. doi:10.1016/j.jacadv.2025.101978.
9. Steffel J, Collins R, Antz M, et al. 2021 European Heart Rhythm Association Practical Guide on the use of non-vitamin K antagonist oral anticoagulants in patients with atrial fibrillation. Europace. 2021;23(10):1612–1676. doi:10.1093/europace/euab065.
10. Fischer U, Koga M, Strbian D, et al. Early versus later anticoagulation for stroke with atrial fibrillation. N Engl J Med. 2023;388(26):2411–2421. doi:10.1056/NEJMoa2303048.
11. Werring DJ, Dehbi HM, Ahmed N, et al. Optimal timing of anticoagulation after acute ischaemic stroke with atrial fibrillation (OPTIMAS): a multicentre, blinded-endpoint, phase 4, randomised controlled trial. Lancet. 2024;404(10464):1731–1741. doi:10.1016/S0140-6736(24)02197-4.
12. Jickling GC, Liu D, Stamova B, et al. Hemorrhagic transformation after ischemic stroke in animals and humans. J Cereb Blood Flow Metab. 2014;34(2):185–199. doi:10.1038/jcbfm.2013.203.
13. Hong JM, Kim DS, Kim M. Hemorrhagic transformation after ischemic stroke: mechanisms and management. Front Neurol. 2021; 12: 703258. doi:10.3389/fneur.2021.703258.
14. Wei C, Liu J, Guo W, et al. Development and validation of a predictive model for spontaneous hemorrhagic transformation after ischemic stroke. Front Neurol. 2021; 12:747026. doi:10.3389/fneur.2021.747026.

ISSN No. 2321-2705 | DOI: 10.51244/IJRSI |Volume XIII Issue XI November 2026

Figure 1

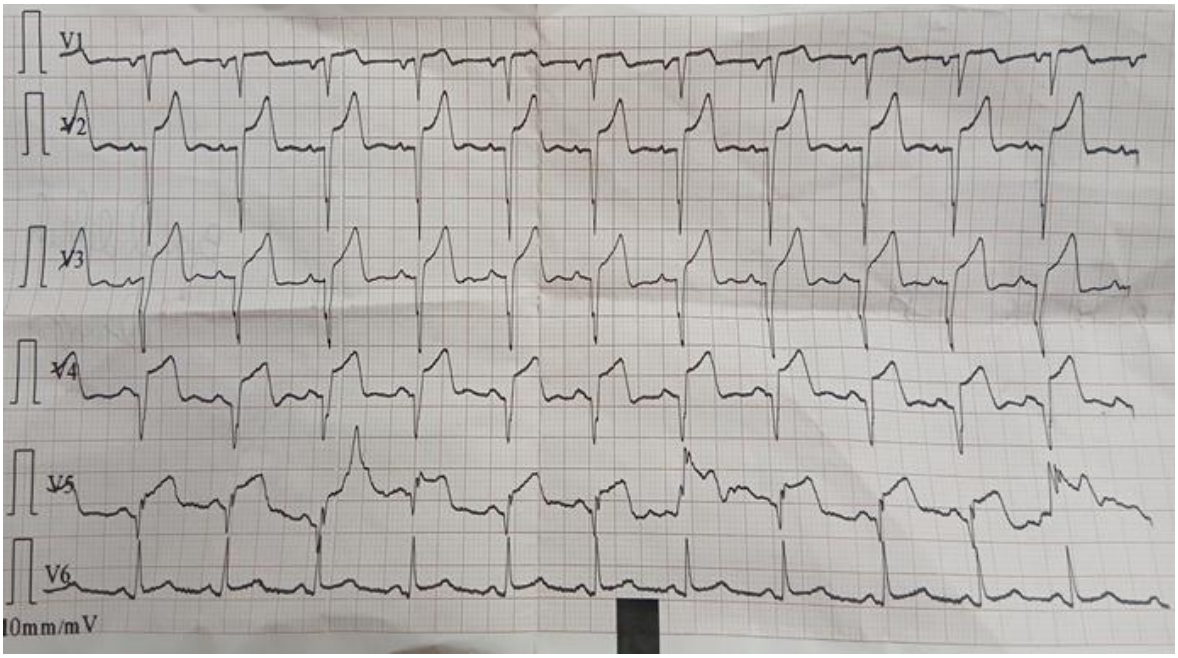

Figure 1. Precordial ECG leads recorded during the stroke admission. Anterior QS complexes with ST-segment elevation and repolarisation abnormalities supported the clinical diagnosis of a previously unrecognized anterior myocardial infarction when interpreted with the history and apical wall-motion abnormality.

Figure 2

A B

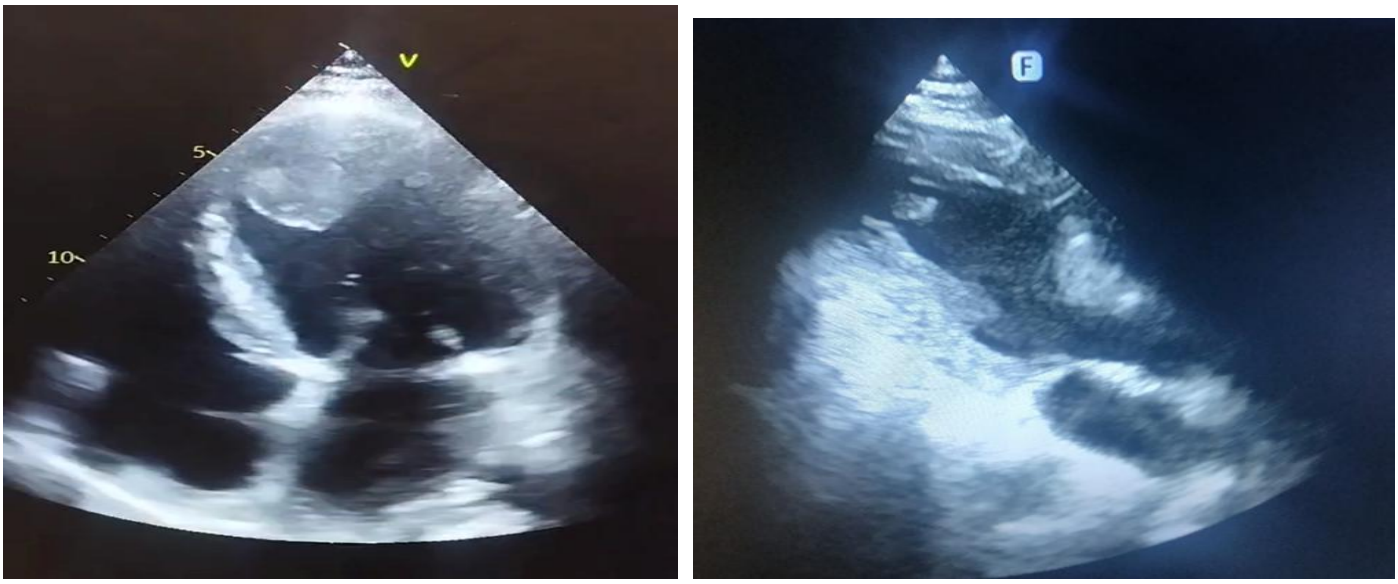

Figure 2. Serial transthoracic echocardiographic assessment of the left ventricular apical thrombus. (A) Admission examination: thrombus measuring 20 × 15 mm attached to the apical wall, with regional apical akinesia and a reported global left ventricular ejection fraction of 57%. (B) Follow-up examination seven months after discharge: residual thrombus measuring 10 × 5 mm under continued rivaroxaban. Dimensions are those reported in the clinical assessments; the displayed images do not include measurement calipers.